

Case Series**The role of locoregional radiotherapy
in distant metastatic nasopharyngeal carcinoma cases****Ika Dewi Mayangsari*, Muhammad Ade Rahman*, Marlinda Adham*,
Gregorius Ben Prajogi**, Rahmat Cahyanur***, Eka Dian Safitri*********Department of Otorhinolaryngology-Head and Neck Surgery, Faculty of Medicine,
Universitas Indonesia/Cipto Mangunkusumo Hospital, Jakarta******Department of Radiation Oncology, Faculty of Medicine,
Universitas Indonesia/Cipto Mangunkusumo Hospital, Jakarta*******Division of Haematology and Oncology, Department of Internal Medicine,
Faculty of Medicine, Universitas Indonesia/Cipto Mangunkusumo Hospital, Jakarta********Clinical Epidemiology and Evidence Based Medicine Unit, Faculty of Medicine,
Universitas Indonesia/Cipto Mangunkusumo Hospital, Jakarta****ABSTRACT**

Background: Nasopharyngeal carcinoma (NPC) is a highly metastatic head and neck cancer primarily treated with platinum-based chemotherapy. The oligometastasis hypothesis proposed by Hellman and Weichselbaum suggested that controlling the primary tumor through locoregional radiotherapy could significantly improve prolonged disease-free survival. **Purpose:** To evaluate the effectiveness of combining locoregional radiotherapy with chemotherapy for metastatic NPC. **Case series report:** The first case involved a 57-year-old male with NPC at T4N3M1 (lungs) with partial response to chemotherapy, who then underwent concurrent chemoradiotherapy. However, his condition deteriorated after completing chemoradiation. The second case featured a 56-year-old male with NPC at T4N3M1 (liver), exhibiting partial response to chemotherapy and remaining at a stable condition after concurrent chemoradiotherapy. **Method:** Using specific keywords based on clinical questions in the PubMed, Cochrane, EBSCOhost, and Proquest databases. Inclusion criteria, exclusion criteria, and critical appraisal were carried out to find relevant studies. **Result:** Eleven articles were appraised critically based on the Oxford Centre for Evidence-based Medicine (CEBM) worksheet and include the validity, importance, and applicability in clinical scenarios. **Conclusion:** Metastatic NPC patients had better overall survival outcomes when treated with locoregional radiotherapy and systemic chemotherapy. Predictive factors influencing survival included oligometastasis, locoregional radiotherapy, chemotherapy response, lactate dehydrogenase, C-reactive protein, EBV DNA, total chemotherapy administration, Karnofsky performance score, number of metastatic lesions, and liver metastases. Platinum-based chemotherapy combined with locoregional radiotherapy could be considered as a management approach for cases of oligometastatic NPC.

Keywords: nasopharyngeal carcinoma, chemotherapy, metastasis, overall survival, radiotherapy

ABSTRAK

Latar belakang: Karsinoma nasofaring (KNF) adalah kanker kepala dan leher dengan kecenderungan tinggi bermetastasis, dan umumnya diobati dengan kemoterapi berbasis platinum. Hipotesis oligometastasis oleh Hellman dan Weichselbaum menyarankan bahwa pengendalian tumor primer melalui radioterapi lokoregional dapat secara signifikan meningkatkan kelangsungan hidup bebas penyakit dalam jangka panjang. **Tujuan:** Untuk mengevaluasi efektivitas dari kombinasi radioterapi lokoregional dengan kemoterapi untuk KNF metastatik, dengan fokus pada kelangsungan hidup keseluruhan. **Laporan kasus:** Kasus pertama seorang pria berusia 57 tahun menderita KNF dengan T4N3M1 (paru), menunjukkan respon parsial terhadap kemoterapi, dan menjalani kemoradioterapi

*secara bersamaan. Namun, kondisinya memburuk setelah menyelesaikan kemoradioterapi. Kasus kedua adalah pria berusia 56 tahun menderita KNF dengan T4N3M1 (hepar), menunjukkan respon parsial terhadap kemoterapi dan mengalami kondisi stabil setelah menjalani kemoradioterapi secara bersamaan. **Metode:** Menggunakan kata kunci spesifik berdasarkan pertanyaan klinis di basis data PubMed, Cochrane, EBSCOhost, dan Proquest. **Kriteria inklusi, kriteria eksklusi, dan penilaian kritis dilakukan untuk menemukan studi yang relevan. Hasil:** Sebelas artikel dinilai secara kritis berdasarkan lembar kerja Oxford Centre for Evidence-based Medicine (CEBM) dan mencakup validitas, pentingnya, dan penerapan dalam skenario klinis. **Kesimpulan:** Pasien dengan KNF metastatik memiliki hasil kelangsungan hidup keseluruhan yang lebih baik saat diobati dengan radioterapi lokoregional dan kemoterapi sistemik. Faktor-faktor prediktif yang mempengaruhi kelangsungan hidup termasuk oligometastasis, radioterapi lokoregional, respon terhadap kemoterapi, laktat dehidrogenase, protein C-reaktif, DNA EBV, total administrasi kemoterapi, skor performa Karnofsky, jumlah lesi metastatik, dan metastasis hepar. Kemoterapi berbasis platinum dikombinasikan dengan radioterapi lokoregional dapat dipertimbangkan sebagai tatalaksana pada kasus KNF dengan oligometastasis.*

Kata kunci: karsinoma nasofaring, kemoterapi, metastasis, kelangsungan hidup, radioterapi

Correspondence address: Ika Dewi Mayangsari. Department of Otorhinolaryngology-Head and Neck Surgery, Faculty of Medicine, University of Indonesia/Cipto Mangunkusumo Hospital, Jakarta.
Email: idmayang@yahoo.com

INTRODUCTION

Nasopharyngeal carcinoma (NPC) is a malignant tumor arising from the epithelium of the nasopharynx. It is a tumor of high incidence and metastasizing tendency, particularly in the Chinese and Southeast Asian population.¹ In Indonesia, it is the fourth most commonly reported cancer of the head and neck region, with a prevalence of 6.2/100,000 people. Male gender is more common with a 2:1 ratio.² The risk of developing NPC increases with a genetic predisposition, environmental factors including smoking, and Epstein-Barr Virus (EBV) infection.³

NPC is challenging to diagnose early due to nonspecific symptoms, including neck lumps, bloody saliva, hearing loss, nosebleeds, nasal congestion, tinnitus, and cranial nerve palsies.^{2,4,5} It is usually diagnosed by endoscopy followed by biopsy of the nasopharyngeal epithelium. Other diagnostic modalities include computed tomography (CT) scan, magnetic resonance imaging (MRI), detection of EBV on biopsied sample or plasma, laboratory tests, and

audiometry to evaluate hearing. Positron emission tomography (PET) scan may be carried out for suspected metastasizing disease or high EBV DNA load.^{2,4} Staging is done according to the TNM system from the American Joint Committee on Cancer (AJCC) 8th edition, while patient performance is evaluated according to The Eastern Cooperative Oncology Group (ECOG) or Karnofsky Performance Score (KPS).^{6,7}

The National Comprehensive Cancer Network (NCCN) of the United States of America (USA), offers a comprehensive overview of the NPC management algorithm, with the 2023 edition emphasizing the latest NPC staging. Radiotherapy is the treatment of choice for non-metastasizing NPC. Palliative radiotherapy may also be used in cases with metastasis to control symptoms and is usually given with chemotherapy, either simultaneously or after.^{6,7} Chemotherapy is given to cases of recurrence or with metastasis, with regimens of cisplatin combined with 5-fluorouracil, paclitaxel, or radiotherapy. Chemotherapy can also be given as a palliative with regimens of methotrexate, capecitabine, or a combination

of cisplatin and gemcitabine.⁶⁻⁸ Surgery may be considered for cases of recurrence or with residual tumors, and usually performed with nasopharyngectomy and cervical lymph node dissection.⁹ Immunotherapy is a new and revolutionary treatment to control inflammation on the tumor bed, and can be given as monotherapy or in combination with chemotherapy.¹⁰

Oligometastasis is a transitional condition of the disease between localized and widely metastatic, in which there is a chance for the disease to be controlled before it spreads extensively. The term was first proposed in 1995 as a hypothesis by Hellman and Weichselbaum, and defined as less than five metastatic lesions in a single site, and no metastasis in other sites. An oligometastasis is considered synchronous if detected in the initial presentation of the cancer itself, and termed metachronous if detected within four to six months after treatment of the primary cancer.^{11,12} The clinical significance of oligometastasis is that there will be a prolonged disease-free survival if both the primary tumor and metastatic lesions are controlled.¹² The 2023 NCCN guidelines underscore systemic therapy for oligometastatic NPC, followed by definitive radiotherapy if a significant response is achieved based on the Response Evaluation Criteria in Solid Tumors (RECIST) criteria.^{13,14} In this report, we presented two cases of NPC complicated by oligometastasis, and discussed the effectiveness of combining locoregional radiotherapy with chemotherapy for metastatic NPC, and the various predictive factors affecting overall survival.

CASE REPORT

CASE 1

A 57-year-old male patient with stage T4N3M1(lung) NPC complained of enlarging lumps in both sides of his neck for the past

5 months. Initial physical examination revealed conglomerated lumps with the largest diameter of 3.5 centimeters at levels II, III, IV bilaterally. The patient had an ECOG status of 1 and no comorbidities. Biopsy results indicated non-keratinized squamous cell carcinoma (SCC), while staging of the NPC revealed extensive nasopharyngeal tumor involving the destruction of the cranial base and clivus, along with multiple lymphadenopathies in bilateral neck regions, and metastatic lesions in the right lung segment 3, and left lung segments 1 and 3.

The patient was treated with 3 cycles of cisplatin-5 fluorouracil chemotherapy followed by 3 cycles of carboplatin-5 fluorouracil chemotherapy, totaling 6 months of treatment. Post-chemotherapy evaluation using nasopharyngeal MRI and thoracoabdominal CT scans showed a decrease in tumor size and metastatic lesions, indicating a partial response. The patient then underwent concurrent chemoradiotherapy with 33 fractions of locoregional radiotherapy, and 3 cycles of cisplatin chemotherapy, completing the treatment in 2 months. Post-radiotherapy evaluation through nasopharyngeal MRI and thoracoabdominal CT scans demonstrated reduced nasopharyngeal mass volume and lymphadenopathy count, but multiple subsolid nodules were detected in both lungs. Based on this evaluation, the patient received the 2nd cycle of docetaxel cisplatin/ carboplatin chemotherapy. Currently, the patient experienced significant fatigue and shortness of breath, with an overall ECOG status of 3.

CASE 2

A 56-year-old male patient diagnosed with T4N3M1(liver) NPC complained of a lump on the left side of the neck for the past 2 years. Physical examination revealed conglomerated lumps, with the largest measuring 2.5 centimeters at levels IB, II, III, IV, V of the left neck region. The patient

had an ECOG status of 1 and a controlled comorbidity of diabetes mellitus managed with oral antidiabetics. Biopsy results from the nasopharynx indicated non-keratinized SCC, while staging showed an extensive nasopharyngeal tumor extending into the left paranasal sinus, retrobulbar orbit, left temporal fossa, involving multiple left lymphadenopathies, and metastatic lesions in the right lobe of the liver.

The patient received 6 cycles of docetaxel-cisplatin chemotherapy over 5 months. Evaluation through nasopharyngeal MRI and thoracoabdominal CT scans showed a reduction in tumor size with no visible neck lymphadenopathy and metastatic lesions in segments 7 and 8 of the liver, exhibiting a partial response to chemotherapy. Subsequently, concurrent chemoradiation was administered, consisting of 33 fractions of locoregional radiotherapy and 2 cycles of cisplatin, 2 cycles of carboplatin, and 1 cycle of cisplatin chemotherapy. Currently, the patient complained of fatigue with an ECOG status of 1. The patient was awaiting the schedule for the evaluation with nasopharyngeal MRI and thoracoabdominal CT scans after chemoradiation.

CLINICAL QUESTION

“In adult patients with metastatic NPC, is locoregional radiotherapy and systemic chemotherapy combination better than systemic chemotherapy alone in terms of overall survival and quality of life?”

PICO

- Population: Adult patients with metastatic NPC
- Intervention: Locoregional radiotherapy and systemic chemotherapy
- Comparison: Systemic chemotherapy
- Outcome: Overall survival percentage, quality of life

“In adult patients with metastatic nasopharyngeal carcinoma (NPC), what factors influence overall survival in those treated with locoregional radiotherapy and systemic chemotherapy?”

PICO

- Population: Adult patients with metastatic NPC treated with locoregional radiotherapy and systemic chemotherapy
- Intervention: Predictive factors
- Comparison: -
- Outcome: Overall survival

METHOD

A literature search was conducted systematically through the PUBMED, Proquest, EBSCO host, and Cochrane databases to address the clinical question using the keywords “nasopharyngeal carcinoma”, “metastasis”, “locoregional radiotherapy”, “chemotherapy”, “survival” and their synonyms. Inclusion criteria for literature search included: (1) systematic review/meta-analysis studies from controlled randomized trials/cohort studies, primary research in the form of controlled randomized trials, or prospective and retrospective cohort studies on metastatic NPC patients who received locoregional radiotherapy and systemic chemotherapy; (2) published within the last 5 years (from 2018 to 2023); (3) outcome defined as overall survival percentage, and (4) written in the English language. Exclusion criteria for literature search included observational and case-control studies. Literature search was followed by filtering for duplicates and screening titles and abstracts for relevance. Full-text reading was carried out on 11 articles. The process was presented in Figure 1.

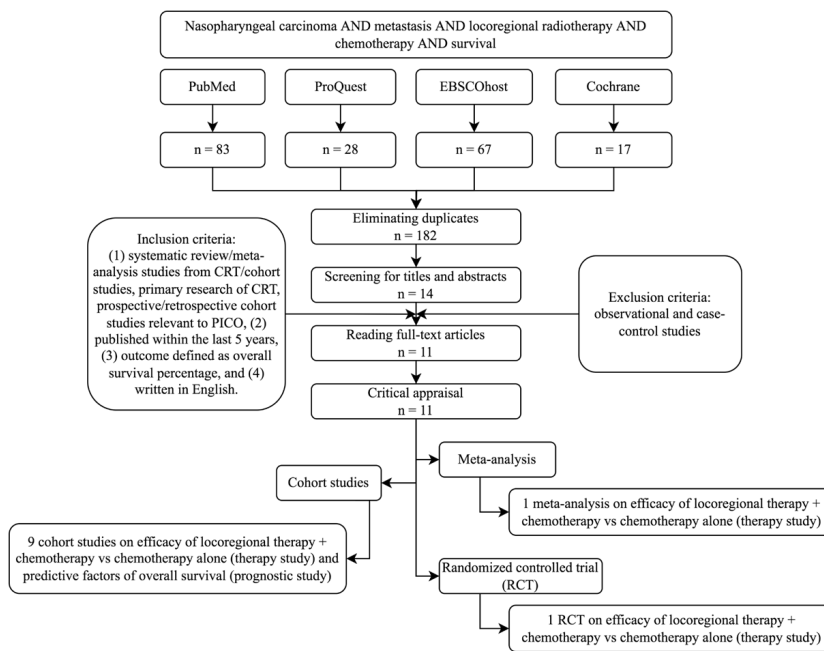


Figure 1. Literature search flowchart.

Literature search obtained 11 articles, one of which was a meta-analysis, 1 was a randomized controlled trial (RCT) and 9 were cohort studies. After the full-text reading, the final 11 articles underwent critical appraisal (available in **Supplementary File**). Q-FAITH was utilized for systematic reviews/meta-analysis and the Centre for Evidence-Based Medicine (CEBM) University of Oxford instrument for primary research such as randomized controlled trials and cohort studies. The validity was assessed based on the levels of evidence by the CEBM University of Oxford (2011).

RESULT

Literature search obtained 11 articles as mentioned above. A study by Wang et al. (2021)¹⁵ was a meta-analysis comprising 15 retrospective studies and 1 controlled randomized trial. Another study by You et al. (2020)¹⁶ was a controlled randomized trial involving metastatic NPC patients who had a complete or partial response after 3 cycles of cisplatin and fluorouracil chemotherapy. Other studies, designed as a cohort studies, focused on metastatic NPC cases treated with locoregional radiotherapy after chemotherapy with varied characteristics. Summary of selected articles is presented in Table 1.

Table 1. Summary of selected studies

First author	Study design (level of evidence)	Number of patients	Median of follow-up	Intervention	Outcome	Predictive factors
Wang et al. (2021) ¹⁵	Meta-analysis of RCT/retrospective studies (1a)	15 studies (1 RCT, 3 case-control, 12 retrospective cohort); a total of 3,402 patients	<6 months	CT+LRT (various doses) vs. CT (platinum-based): 2,015 vs. 1,387	Pooled HR (OS): 0.45 (95% CI: 0.40–0.51); pooled HR (PFS): 0.37 (95% CI: 0.29–0.49); pooled RR (ORR): 0.60 (95% CI: 0.46–0.79); pooled RR (DCR): 0.77 (95% CI: 0.71–0.85)	NR

You et al. (2020) ¹⁶	Randomized clinical trial/RCT (1b)	126 patients	26.7 months	CT+LRT (IMRT) vs. CT (PF): 63 vs. 63	24-month OS of CT+LRT vs. CT: 76.4% vs. 54.5%; HR (OS): 0.42 (95% CI, 0.23-0.77); HR (PFS): 0.36 (95% CI, 0.23-0.57); ORR of CT+LRT vs. CT: 80.9% vs. 82.5%	NR
Zheng et al. (2022) ¹⁷	Retrospective cohort (2b)	355 patients	50.8 months	PCT+CCRT vs. PCT+RT (conventional or IMRT): 163 vs. 192	5-year OS of PCT+CCRT: 53.0%; median OS time: 60 months	CCRT (HR of OS: 0.59 [95% CI: 0.39–0.88]), male gender (HR of OS: 0.50 [95% CI: 0.27–0.94]), >3 cycles of CT (HR of OS: 0.27 [95% CI: 0.09–0.77]), local therapy for metastasis (HR of OS: 0.69 [95% CI: 0.45–1.05])
Zeng et al. (2021) ¹⁸	Retrospective cohort (2b)	168 patients	44 months	PCT+LRT (IMRT) vs. PCT (platinum-based): 109 vs. 59	3-year OS of CT+LRT vs. CT: 66.3% vs. 25.2%; median OS time: 57 months vs. 22 months	KPS>80 (HR of OS: 0.614 [95% CI: 0.371–1.017]), LRT (HR of OS: 0.533 [95% CI: 0.319–0.889]), oligometastasis (HR of OS: 0.548 [95% CI: 0.331–0.907])
Ni et al. (2021) ¹⁹	Retrospective cohort (2b)	129 patients	51.5 months	CT (platinum-based) + LRT (IMRT): 129 patients	5-year, 3-year, 2-year, 1-year OS: 47%, 58%, 71%, 88%; median OS time: 54.2 months	Pre-treatment SLDH>180 U/L (HR of OS: 1.931 [95% CI: 1.134-3.287]), chemotherapy cycles <4 (HR of OS: 2.870 [95% CI: 1.183-6.965]), polymetastasis (HR of OS: 5.632 [95% CI: 2.074-15.254])
Dizdar et al. (2021) ²⁰	Retrospective cohort (2b)	35 patients	25 months	CT+LRT (60-74 Gy): 35 patients	4-year, 2-year OS: 34%, 51%.	No significant effects of age, gender, oligometastasis, liver metastasis, or RT dose.

Li et al. (2021) ²¹	Retrospective cohort (2b)	244 patients	62.7 months	CT (platinum-based) + LRT: 244 patients	5-year, 3-year, 1-year OS: 49.4%, 63.5%, 91.7%; median OS time: 60.9 months	CRP (HR of OS: 1.02 [95% CI: 1.01-1.04]), single metastatic site (HR of OS: 0.53 [95% CI: 0.29-0.96]), liver metastasis (HR of OS: 2.11 [95% CI: 1.18-3.76]), post-treatment EBV DNA (HR of OS: 2.62 [95% CI: 1.59-4.31]), stable/progressive disease (HR of OS: 4.10 [95% CI: 1.55-10.86])
Yang et al. (2021) ²²	Retrospective cohort (2b)	94 patients	Not clearly stated; 16.0% had a follow-up time \geq 36 months	CT vs. RT during CT vs. RT after CT: 28 vs. 31 vs. 35	3-year, 2-year, 1-year OS of CT group: 0, 32.1%, 75.0%; RT during CT group: 12.9%, 54.8%, 77.4%; RT after CT group: 31.4%, 71.4%, 85.7%; median OS time of CT group: 16 months; RT during CT group: 25.0 months; RT after CT group: 29.0 months	HBV infection (HR of OS: 0.48 [95% CI: 0.24-0.93]), the number of distant metastatic lesions (HR of OS: 0.43 [95% CI: 0.25-0.73]), liver metastases (HR of OS: 0.55 [95% CI: 0.31-0.97]), radiotherapy (HR of OS: 4.41 [95% CI: 2.27-8.57]), treatment response (HR of OS: 0.07 [95% CI: 0.01-0.39])
Liao et al. (2020) ²³	Retrospective cohort (2b)	150 patients	23.7 months	CT+LRT vs. CT: 117 vs. 33	3-year OS CT+LRT vs. CT: 44.9% vs. 24.8%; median OS time of CT+LRT vs. CT: 34.0 months vs. 15.2 months	Sites of metastasis significantly lowered overall survival; HR (OS) of M1b vs. M1a: 2.152 (95% CI, 1.253-3.696); HR (OS) of M1c vs. M1a: 4.169 (95% CI, 1.464-11.871)

Du et al. (2022) ²⁴	Retrospective cohort (2b)	118 patients	31.5 months	CT (taxane/gemcitabine-based) + LRT (IMRT): 118 patients	5-year OS: 44%; 5-year PFS: 34.2%; 5-year DMFS: 41.1%; 5-year LRFS: 82.6%	High lymphocyte count (HR of PFS: 0.236; HR of OS: 0.518, p = 0.04); M sub-division (HR (OS) of M1b vs M1a: 4.107; HR (OS) of M1c vs M1a: 3.083)
Shuang et al. (2022) ²⁵	Retrospective cohort (2b)	39 patients	38 months	CT (platinum-based) + LRT (54-78 Gy): 39 patients	5-year, 3-year, 1-year OS: 57.9%, 70%, 97%; 5-year, 3-year, 1-year PFS: 50.9%, 59%, 86.9%	Age (HR of OS: 3.741 [95% CI: 1.061–13.184]), numbers of metastases lesions (HR of OS: 5.033 [95% CI: 1.563–16.205]), CT cycles (HR of OS: 0.277 [95% CI: 0.108–0.707]), schemes of chemotherapy (HR of OS: 2.779 [95% CI: 0.979–7.891])

OS, overall survival; PFS, progression free survival; DMFS, distant metastasis relapse free survival; LRFS, local regional recurrence free survival; ORR, objective response rate; DCR, disease control rate; HR, hazard ratio; CI, confidence interval; NR, not reported; CT, chemotherapy; PCT, palliative chemotherapy; LRT, locoregional radiotherapy; IMRT, intensity-modulated radiation therapy; CCRT, concurrent chemoradiotherapy; PF, cisplatin and 5-fluorouracil; KPS, Karnofsky Performance Score; SLDH, serum lactate dehydrogenase; CRP, C-reactive protein

DISCUSSION

Radioterapy and concurrent chemotherapy are the current recommended therapy for advanced locoregional NPC cases, while chemotherapy is recommended for cases that have metastasized. However, providing locoregional radiotherapy for metastasized NPC has been quite a challenge. In cases with oligometastasis, there is a potential of disease control and prolonged survival if the primary tumor can be controlled with therapy.^{11,12} From our literature search, we found that all 11 articles reported better outcomes in cases treated with combination of chemotherapy and locoregional radiotherapy, compared to those treated with chemotherapy or radiotherapy

alone. However, various prognostic factors might influence outcome in these cases, and should be taken into consideration when choosing therapy.

A meta-analysis study by Wang et al. (2021)¹⁵ reported that combining chemotherapy and locoregional radiotherapy is superior to chemotherapy alone, irrespective of heterogeneity. The hazard ratio for overall survival was 0.49 in retrospective studies and 0.42 in randomized controlled trials by You et al. (2020).¹⁶ The comparison between the two studies showed no statistically significant difference with a p-value of 0.85. You et al. (2020)¹⁶ reported an overall survival rate of 76.4% at 24 months. A

study by Ni et al. (2021)¹⁹ reported overall survival rates after induction chemotherapy followed by locoregional radiotherapy for metastasized NPC in the 1st, 2nd, 3rd, and 5th year, which were 99%, 71%, 58%, and 47%, respectively. Li et al. (2021)²¹ concluded a similar outcome, with a survival rate of 91.7% in the 1st year, 63.5% in the 3rd year, and 49.4% in the 5th year after giving at least 2 cycles of chemotherapy before locoregional radiotherapy for metastasized NPC. Shuang et al. (2022)²⁵ reported the overall survival after locoregional radiotherapy for post-chemotherapy NPC, emphasizing the oligometastasis condition, which was 97% in the 1st year, 70% in the 3rd year, and 57.9% in the 5th year.

Wang et al. (2021)¹⁵ conducted a meta-analysis on retrospective studies, finding significant heterogeneity in the population (I² value of 55%). The calculated outcome hazard ratio was 0.49 (95% CI, 0.41-0.57). Due to this heterogeneity, one retrospective study by Sun et al. (2019)²⁶ was excluded. This study focused on identifying optimal candidates for local treatment of the primary tumor in de novo metastatic nasopharyngeal carcinoma. They analyzed 502 metastatic NPC patients, revealing reduced effectiveness of locoregional radiotherapy in a high-risk subgroup characterized by detected EBV DNA and inadequate chemotherapy response (outcome hazard ratio of 0.76). After excluding the said study, the obtained processed data showed lower heterogeneity (I² = 20%) and an outcome hazard ratio of 0.45 (95% CI, 0.40-0.51).

NPC is a head and neck tumor with a high metastatic potential. Distant metastasis is a major factor affecting the overall survival of NPC patients and clinical management failure. The management of metastatic NPC is expected to reduce disease progression and extend overall patient survival. The study by Wang et al. (2021)¹⁵ addressed this challenge by assessing the hazard ratio

outcome of progression-free survival in the chemotherapy and radiotherapy group versus the chemotherapy-only group, which was 0.37 (95% CI, 0.29-0.49). You et al. (2020)¹⁶ also reported that post-chemotherapy locoregional radiotherapy in metastatic NPC was more effective compared to no radiotherapy, with a hazard ratio of 0.36 (95% CI, 0.23-0.57). Additionally, Yang et al. (2021)²² found that progression-free survival rates in the post-chemotherapy radiotherapy group was better: 88.6% at 6 months, 48.6% at year-1, and 22.9% at year-2. Shuang et al. (2022)²⁵ reported progression-free survival rates in the locoregional radiotherapy group for oligometastatic NPC post-treatment, which were 86.9% in year-1, 65.3% in year-2, 59% in year-3, and 60.9% in year-5. In a recent study by Du et al. (2022)²⁴ on metastatic NPC cases treated with taxane-based chemotherapy followed by locoregional radiotherapy, a 5-year progression-free survival rate of 34.2% was obtained.

Several cohort studies on administering locoregional radiotherapy after chemotherapy in metastatic NPC had assessed factors influencing overall survival. Zheng et al. (2022)¹⁷ reported predictive factors for overall survival in metastatic NPC through multivariate analysis, including concurrent chemoradiotherapy, male gender, more than 3 cycles of chemotherapy, and local therapy for metastatic lesions, prolonging overall survival with hazard ratios of 0.59, 0.50, 0.27, and 0.69, respectively. On the other hand, multiple liver organ metastases and multimetastasis affected overall survival with hazard ratios of 1.95 and 1.97. Zeng et al. (2021)¹⁸ added other predictive factors such as Karnofsky Performance Scale above 80, locoregional radiotherapy, and oligometastasis, also extending overall survival in NPC, with hazard ratios of 0.614, 0.533, and 0.548, respectively. Ni et al. (2021)¹⁹ further included prognostic factors such as lactate dehydrogenase exceeding

180 units per liter before radiotherapy and polymetastasis, reducing overall survival with hazard ratios of 1.931 and 5.632. Li et al. (2021)²¹ also examined predictive factors for metastatic NPC, namely C-reactive protein levels, detected EBV DNA, and stable disease/progressive disease after chemotherapy, which might reduce overall survival with hazard ratios of 1.02, 2.62, and 4.10. Studies by Yang et al. (2021)²² and Liao et al. (2020)²³ conducted multivariate analyses on prognostic factors in metastatic NPC, finding that an increasing number of metastatic lesions and sites of metastasis significantly lowered overall survival.

In conclusion, metastatic NPC patients had better overall survival outcomes, ranging from 29 to 60.9 months, when treated with locoregional radiotherapy and systemic chemotherapy. Predictive factors influencing survival in patients treated with a combination of locoregional radiotherapy and systemic chemotherapy included oligometastasis, locoregional radiotherapy, chemotherapy response, lactate dehydrogenase, C-reactive protein, EBV DNA, total chemotherapy administration, Karnofsky performance score, number of metastatic lesions, and liver metastases.

Two cases of metastatic NPC were reported, characterized by oligometastasis, and treated with locoregional radiotherapy after chemotherapy, to achieve a longer overall survival. Platinum-based chemotherapy combined with locoregional radiotherapy, either after or concurrent with chemotherapy (with a minimum of 1 cycle and complete response/partial response), may be considered as a management approach for cases of oligometastatic nasopharyngeal carcinoma (NPC).

REFERENCE

1. Almomani MH, Zulfiqar H, Nagalli S. Nasopharyngeal Carcinoma (NPC, Lymphoepithelioma). In: StatPearls [Internet]. 2023. Available from: <https://www.ncbi.nlm.nih.gov/books/NBK558922/>
2. Flint PW, Haughey BH, Lund VJ, Niparko JK, Robbins KT, Thomas JR, et al. Cummings Otolaryngology Head and Neck Surgery. 6th ed. Philadelphia: Elsevier Saunders; 2015.
3. Tsao SW, Yip YL, Tsang CM, Pang PS, Lau VMY, Zhang G, et al. Etiological factors of nasopharyngeal carcinoma. *Oral Oncol* [Internet]. 2014;50(5):330–8. Available from: <http://dx.doi.org/10.1016/j.oraloncology.2014.02.00>
4. Bossi P, Chan AT, Licitra L, Trama A, Orlandi E, Hui EP, et al. Nasopharyngeal carcinoma: ESMO-EURACAN Clinical Practice Guidelines for diagnosis, treatment and follow-up. *Ann Oncol* [Internet]. 2021;32(4):452–65. Available from: <https://doi.org/10.1016/j.annonc.2020.12.007>
5. Abdullah B, Balasubramanian A, Lazim NM. An Evidence-Based Approach to the Management of Nasopharyngeal Cancer: From Basic Science to Clinical Presentation and Treatment. 1st ed. United Kingdom: Academic Press; 2020.
6. Farhat, Adham M, Dewi YA, Indrasari SR, editors. *Karsinoma Nasofaring*. 1st ed. Jakarta: EGC; 2021.
7. Keputusan Menteri Kesehatan Republik Indonesia. Pedoman Nasional Pelayanan Kedokteran Tata Laksana Kanker Nasofaring. Jakarta: Kementerian Kesehatan; 2019.
8. Chen YP, Chan ATC, Le QT, Blanchard P, Sun Y, Ma J. Nasopharyngeal carcinoma. *Lancet* [Internet]. 2019;394(10192):64–80. Available from: [http://dx.doi.org/10.1016/S0140-6736\(19\)30956-0](http://dx.doi.org/10.1016/S0140-6736(19)30956-0)
9. Lund VJ, Howard DJ, Wei WI. Tumors of the Nose, Sinuses, and Nasopharynx. Stuttgart: Thieme; 2014.
10. Xu JY, Wei XL, Wang YQ, Wang FH. Current status and advances of immunotherapy in nasopharyngeal carcinoma. *Ther Adv Med Oncol*. 2022;14:17588359221096214.
11. Bahig H, Huang SH, O’Sullivan B. Oligometastatic Head and Neck Cancer: Challenges and Perspectives. *Cancers (Basel)*. 2022;14(16):1–14.

12. Reyes DK, Pienta KJ. The biology and treatment of oligometastatic cancer. *Oncotarget*. 2015;6(11):8491–524.
13. Eisenhauer EA, Therasse P, Bogaerts J, Schwartz LH, Sargent D, Ford R, et al. New response evaluation criteria in solid tumours: Revised RECIST guideline (version 1.1). *Eur J Cancer* [Internet]. 2009;45(2):228–47. Available from: <http://dx.doi.org/10.1016/j.ejca.2008.10.026>
14. National Comprehensive Cancer Network. NCCN Clinical Practice Guideline in Oncology: Head and Neck Cancers (Version 2023) [Internet]. 2023 [cited 2023 May 1]. Available from: https://www.nccn.org/professionals/physician_gls/pdf/head-and-neck.pdf
15. Wang G, Shen L. The efficacy of locoregional radiotherapy plus chemotherapy vs. chemotherapy alone in metastatic nasopharyngeal carcinoma: A meta-analysis. *Ann Palliat Med*. 2021;10(3):2584–95.
16. You R, Liu YP, Huang PY, Zou X, Sun R, He YX, et al. Efficacy and Safety of Locoregional Radiotherapy with Chemotherapy vs. Chemotherapy Alone in de Novo Metastatic Nasopharyngeal Carcinoma: A Multicenter Phase 3 Randomized Clinical Trial. *JAMA Oncol*. 2020;6(9):1345–52.
17. Zheng SH, Wang YT, Liu SR, Huang ZL, Wang GN, Lin JT, et al. Addition of chemoradiotherapy to palliative chemotherapy in de novo metastatic nasopharyngeal carcinoma: a real-world study. *Cancer Cell Int* [Internet]. 2022;22(1):1–11. Available from: <https://doi.org/10.1186/s12935-022-02464-7>
18. Zeng F, Lu T, Xie F, Chen L, Zhang L, Su Y, et al. Effects of locoregional radiotherapy in de novo metastatic nasopharyngeal carcinoma: A real-world study. *Transl Oncol* [Internet]. 2021;14(11):101187. Available from: <https://doi.org/10.1016/j.tranon.2021.101187>
19. Ni M, Geng L, Kong F, Du C, Zhai R, Lyu Y, et al. Induction Chemotherapy Combined with Intensity-Modulated Radiotherapy for 129 Nasopharyngeal Carcinoma Patients with Synchronous Metastases: A Retrospective Study. *Front Oncol*. 2021;11(May):1–9.
20. Dizdar Y, Özkaya Toraman K, Altun U. Locoregional treatment for de novo metastatic nasopharyngeal carcinoma. *Turk Onkol Derg*. 2021;36(2):177–83.
21. Li WZ, Hua X, Xie DH, Liang H, Liu GY, Xia WX, et al. Prognostic model for risk stratification of de novo metastatic nasopharyngeal carcinoma patients treated with chemotherapy followed by locoregional radiotherapy. *ESMO Open*. 2021;6(1):1–10.
22. Yang Y, Li X, Zhou P, Deng X, Wang Y, Dang Q, et al. Survival effects of radiotherapy on patients newly diagnosed with distant metastatic nasopharyngeal carcinoma in non high incidence areas. *Cancer Manag Res*. 2021;13(November):8169–78.
23. Liao W, He J, Gou Q, Duan B, Liu L, Ai P, et al. Synchronous metastatic nasopharyngeal carcinoma: Characteristics and survival of patients adding definitive nasopharyngeal-neck radiotherapy to systematic chemotherapy. *Cancer Manag Res*. 2020;12:10211–9.
24. Du C, Ni M, Jiang J, Kong F, Zhai R, Lu Y, et al. Taxane/gemcitabine-containing chemotherapy plus locoregional IMRT for patients with de novo metastatic nasopharyngeal carcinoma: the treatment outcomes and prognostic factors analysis. *Eur Arch Otorhinolaryngol* [Internet]. 2022;279(8):3947–56. Available from: <https://doi.org/10.1007/s00405-021-07192-8>
25. Shuang H, Feng J, Caineng C, Qifeng J, Tin J, Yuanyuan C, et al. The value of radical radiotherapy in the primary tumor of newly diagnosed oligometastatic nasopharyngeal carcinoma patients. *Clin Transl Oncol* [Internet]. 2019;21(2):213–9. Available from: <https://doi.org/10.1007/s12094-018-1911-7>