

Case Report**Co-occurrence of chronic rhinosinusitis with nasal polyps and neurofibroma**

Dolly Irfandy*, **Bestari Jaka Budiman***, **Khairani Ayunanda Ikhlas***,
Pamelia Mayorita**

*Division of Rhinology, Department of Otorhinolaryngology Head & Neck Surgery,

**Division of Pathologic Anatomy,
Faculty of Medicine Universitas Andalas, Padang

ABSTRACT

Background: Nasal polyps are painless inflammatory lesions originated from around the middle meatus or paranasal sinus cavity; while neurofibroma is benign peripheral nerve sheath tumor. **Purpose:** To report a rare case of neurofibroma concurrently with nasal polyps in chronic rhinosinusitis. **Case report:** A 64-year-old female with chief complaint congestion on the right nose cavity. There was a mass on both nasal cavities. Patient diagnosed with benign mass at right nasal cavity and chronic rhinosinusitis with nasal polyps at left nasal cavity; with a differential diagnosis of chronic rhinosinusitis with bilateral nasal polyps. Computer tomography scan results showed homogeneous isodense lesion in the right nasal cavity, and mucosal thickening in left nasal cavity and maxillary sinus. Patient was managed with total extirpation of the bilateral nasal cavity mass and functional endoscopic sinus surgery. Pathological examination revealed neurofibroma in the right nasal cavity and polyps in the left nasal cavity. **Clinical question:** "How to differentiate inflammation with tumor of nasal and paranasal sinuses? Is there a causal relationship?" **Review method:** Literature searching was performed with the keywords "nasal cavity neurofibroma", AND "nasal polyps", AND "chronic rhinosinusitis" through database Google Scholar, PubMed, and hand searching/e-book. **Result:** There were 11 literatures published in the last 5 years, and 7 articles relevant with the subject. **Conclusion:** Chronic rhinosinusitis with nasal polyps, along with neurofibroma on nasal cavity is a rare co-occurrence, and there was no correlation between those lesions. Pathological examination is a gold standard in differentiating a definite diagnosis of neurofibromas and polyps.

Keywords: nasal cavity neurofibroma, nasal polyps, chronic rhinosinusitis

ABSTRAK

Latar belakang: Polip adalah lesi jinak tanpa rasa nyeri, yang berasal dari sekitar meatus medius atau rongga sinus paranasal; sedangkan neurofibroma dikenal sebagai tumor jinak selubung saraf perifer. **Tujuan:** Melaporkan kasus yang jarang, neurofibroma bersamaan dengan polip nasi pada sinusitis kronik. **Laporan kasus:** Seorang wanita 64 tahun datang dengan keluhan utama hidung sebelah kanan tersumbat, yang memberat sejak 4 bulan terakhir. Didapati massa pada kedua kavum nasi, tetapi lebih besar pada sisi kanan. Pasien didiagnosis massa jinak kavum nasal kanan, rinosinusitis kronis dengan polip pada kavum nasi kiri; dibuat diagnosis kerja rinosinusitis kronik disertai polip nasi bilateral. Hasil CT scan menunjukkan lesi isodens homogen pada kavum nasi kanan, serta penebalan mukosa pada kavum nasi dan sinus maksilaris kiri. Penatalaksanaan dengan ekstirpasi total massa kavum nasi bilateral, dan bedah sinus endoskopi fungsional. Pemeriksaan patologi menunjukkan neurofibroma di kavum nasi kanan, dan polip di kavum nasi kiri. **Pertanyaan klinis:** "Bagaimana membedakan peradangan dengan tumor hidung dan sinus paranasal? Apakah ada hubungan kausal?" **Tinjauan literatur:** Pencarian literatur dilakukan menggunakan kata kunci "nasal cavity neurofibroma", DAN "nasal polyps", DAN "chronic rhinosinusitis" pada database Google Scholar, PubMed, dan hand searching/e-book. **Hasil:** Didapati 11 literatur yang terbit dalam 5 tahun terakhir, dan 7 artikel sesuai dengan subjek. **Kesimpulan:** Rinosinusitis kronis dengan polip nasi bersamaan dengan neurofibroma

pada kavum nasi adalah kejadian yang jarang terjadi, dan tidak ada korelasi diantara lesi-lesi tersebut. Pemeriksaan patologi merupakan baku emas untuk menegakkan diagnosis pasti dalam membedakan polip dan neurofibroma.

Kata kunci: *neurofibroma kavum nasi, polip hidung, rinosinusitis kronik*

Correspondence address: Dolly Irfandy. Division of Rhinology, Department of Otorhinolaryngology Head & Neck Surgery, Faculty of Medicine Universitas Andalas, Padang.
Email: dollyirfandy@med.unand.ac.id

INTRODUCTION

Inflammation, and tumor of nasal and paranasal sinuses are a field of great interest in Rhinology worldwide due to its increasing frequency, as well as many aspects related to their etiology, contradictory clinical manifestations, and multitude of therapeutic options.¹ Rhinosinusitis is a common condition globally, leading to a significant burden on society in terms of healthcare costs, and decreasing productivity.² Tumors of nose and paranasal sinuses could emerge in any age. Benign tumors are common in third and fourth decades, whereas malignant tumors in fifth and sixth decades.³

The most often presenting symptoms in both benign and malignant tumors are bleeding from the nose and nasal obstruction.^{3,4} These symptoms need a detailed clinical evaluation. Nasal endoscopy and Computer Tomography Scanning (CT-scan) are important in the diagnosis and management of these tumors.³

The more common tumor types are of epithelial origin and include benign neoplasms (Schneiderian papilloma) and malignant neoplasms (squamous cell carcinoma).⁴ Histopathological (HP) examinations is the most important element in tumor diagnosis.¹

Chronic rhinosinusitis (CRS) with nasal polyps as inflammatory disease, along with neurofibroma on nasal cavity as tumor is a rare co-incidence, is there any correlation between these lesions?

CASE REPORT

A 64-years-old female was referred from Bangko village to ENT outpatient clinic of RSUP. Dr. M. Djamil, Padang, on October 29th, 2021 with working diagnosis of benign mass on the nasal cavities. The patient complained of congestion on the right nostril, which was getting worse in the past 4 months. It seemed like flesh was growing that made her right nose feel stuffy, since 2 years previously. There was no rhinorrhea, nor post nasal drip. There was no history of blood flowing from the nose. There was a decrease sense of smell on the right nostril. There was history of toothache on the right and left upper molar. There was occasional headache. There was no pain on cheek, nose, and face. There was no discomfort of the face and gums, nor bad odor. There was no history of sneezing when exposed to dust/cold air. There was no history of asthma. There was no decrease of body weight. There was no lump on neck, and there was no family history of hypertension and diabetes mellitus. Patient had not any therapy before. Sino-nasal Outcome Test (SNOT) questionnaire score was 13, and nasal obstruction symptom evaluation score was 8.

On physical examination, the general condition was good, compos mentis, cooperative. Blood pressure 120/80 mm Hg, pulse rate 84x/minute, and respiratory rate 17x/minute. Otoscopy and throat examination were within normal limits. On anterior rhinoscopy, the right nostril was filled with mass, round shaped, skin colored, sleek

surface, mobile and not easily bleed. Inferior turbinate, middle turbinate and septum could not be evaluated, and there was no discharge. There was also a mass in left nostril, oval shaped, pink in color, sleek surface, mobile and not easily bleed. Inferior turbinate and middle turbinate were eutrophy, no septal deviation, and there was some mucoid discharge. There were multiple radix and dental caries in oral cavity. There was no lump on neck. Peak nasal inspiratory flow was 60. There was no other mass or café-au-lait spots on her body. There were no Lisch nodules in both eyes.

On nasoendoscopic examination, there was mass filling the right and left nostrils, round shaped, skin colored, sleek surface, mobile, and not easily bleed. Inferior and middle turbinates were eutrophy, there was septal deviation, and minimal mucoid discharge (Figure 1). There was no mass at nasopharynx.

Patient was diagnosed with benign mass at right nasal cavity, and chronic rhinosinusitis with nasal polyp (CRSwNP) at left nasal cavity; and differential diagnosed with bilateral CRSwNP. Patient received corticosteroid tapering off therapy, and then CT-Scan was performed (Figure 2). It revealed a relatively homogeneous isodense lesion (HU 20-28) in the right nasal cavity, which was well demarcated, measuring 1.8x1.4x1.6 cm. Mucosal thickening were seen in the left nasal cavity and bilaterally maxillary sinuses, notably on the left side. There was septal deviation, bilateral medial bent uncinata processes, and pneumatization of the left middle turbinate, with Lund-Mackay score 9. There was no abnormality of sphenoid sinus and no mass at retro-orbital area. After corticosteroid tapering off had been administered, there was no decrease of tumor in size. The patient was planned, and had signed informed consent for bilateral nasal cavity mass extirpation and Functional Endoscopic Sinus Surgery (FESS).

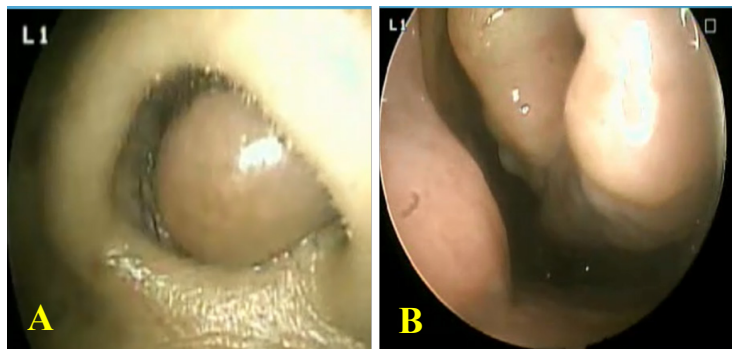


Figure 1. Nasoendoscopy of patient. A. right nasal cavity. B. Left nasal Cavity

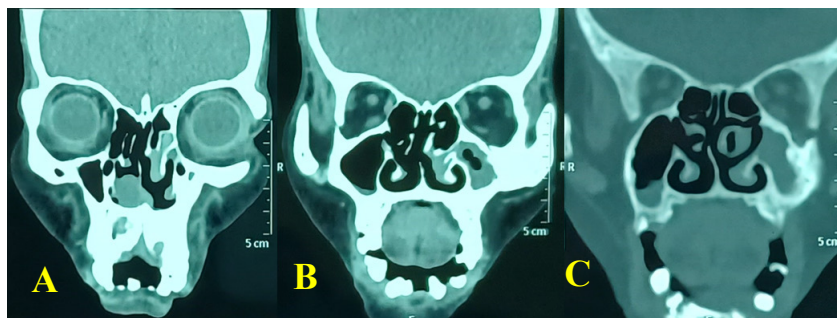


Figure 2. CT scan of paranasal sinus. A. There was relatively homogeneous isodense lesion (HU 20-28) in the vestibule of right nasal cavity on right nasal cavity. B. Mucosal covering and thickening were seen in the left nasal cavity and left maxillary sinuses, and medial bent of uncinata. C. There was pneumatization of left middle turbinate.

The patient was consulted to the Dental and Oral Department on November 23th, 2021 to see if there was a focal infection. On intraoral examination there were residual roots of upper left tooth 6, 7, and 8, and there was loose of lower right tooth 2 and 4, and lower left tooth 1, 2 and 4 due to tooth extrusion with grade III mobility. The patient was recommended for tooth extraction.

The chest X-ray showed no abnormalities. Blood examination, Hb 11.1 g/dl, leukocytes 9,240/mm³, platelets 279,999/mm³, hematocrit 31%, neutrophilia, albumin and total protein slightly decreased. Patient was given antibiotic therapy Ceftriaxone 2x1g intravenously one day before surgery.

Extirpation of mass and FESS was performed on November 30th 2021, under general anesthesia. Epinephrine 1:200,000 packings were placed in both nasal cavities. In the right nose, the mass filled the cavity with the stalk attached to the lateral wall, and there was medial bent unciniate process. After adrenalin infiltration on the stalk of the mass, followed by cauterization, the mass was then extirpated, 2.4x1.8x0.7 cm in size. The ostium of right maxillary sinus was identified, then uncinectomy and antrostomy were performed. Ostium to frontal ethmoid was visible.

On left nasal cavity, there was a polypoid mass originating from the left middle meatus, and unciniate process extending to the medial turbinate. Infiltration was performed on the left unciniate, followed by uncinectomy and extirpation of the mass; and conchotomy was performed at bullous medial turbinate; and after that, ethmoidectomy and widening of the left maxillary sinus ostium. Then, the maxillary sinus cavity was cleaned.

Anterior packings were placed bilaterally. The patient was given post-operative therapy of ceftriaxone 2x1 gr and dexamethasone 3x5 mg intravenously, and paracetamol 3x500 mg orally.

On the first day of follow-up, there was no blood came out through the anterior tampons, or flowed down the throat. Patient had no fever and no headache. Anterior tampons were removed on the third post-operative day. There was no blood coming out from the nose, nor flowing down into the throat. The patient was discharged with home medication Cefixime 2x200 mg orally and paracetamol 3x500 mg orally.

On the 7th day post-operative examination, patient complained of nasal congestion. There was no blood came out from the nose or flowed into the throat, nor headache, nor fever. Nasoendoscopic examination revealed crusts in both nasal cavities, which were then cleaned. There was no mass and neither attachment of medial turbinate to lateral wall of nasal cavity.

Histopathology examination result stated that on the right nasal cavity: a lump of mass laminated by stratified squamous epithelium, with myxoid stroma which contained spindle cells, lymphocytes, plasma cells, and blood vessels, with a diagnosis of neurofibroma (Figure 3).

On left nasal cavity: there were several lumps of polypoid mass laminated by respiratory epithelium, with loose connective tissue stroma which contained lymphocytes, plasma cells, eosinophils, and clusters of seromucous glands, some of which were cystic, and bits of cartilage (Figure 4).

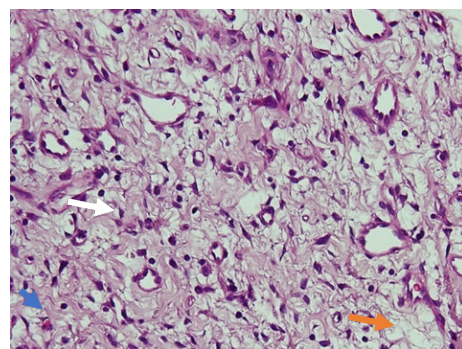


Figure 3. Pathology magnification 40x10 on the right nasal cavity. There are wavy nuclei (white arrow), blood vessel (blue arrow), and myxoid stroma (orange arrow)

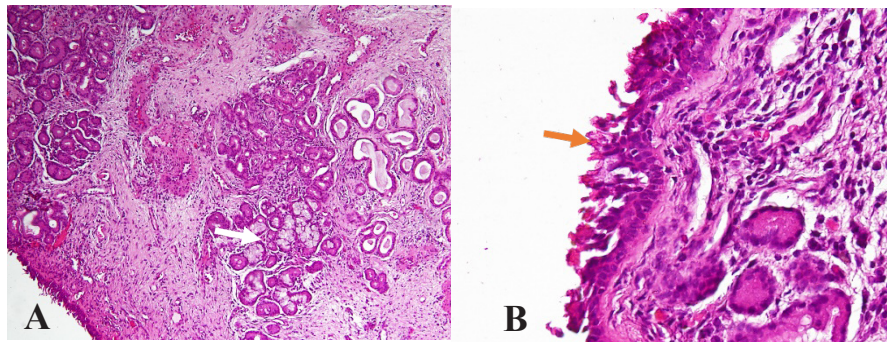


Figure 4. Pathology examination on the of left nasal cavity. A. Magnification 10x10, seromucous glands (white arrow). B. Magnification 40x10, eosinophil (blue arrow), respiratory epithelium (orange arrow).

The pathologic diagnosis was nasal polyps, allergic type. The patient was given saline nasal spray therapy, and continued antibiotic for 10 days.

On 2 weeks post-operative visit in outpatient clinic, there was no complaint of nasal congestion; no blood came out from the nose, nor flowing down into the throat. There was no headache, nor fever. On nasoendoscopic examination, there was no crusts in both nasal cavities. There was no mass, and no attachment of the medial turbinate to the lateral side of nasal cavity. Patient was given nasal irrigation, and scheduled for follow up the next month.

CLINICAL QUESTION

“How to differentiate inflammation process with tumor of nasal and paranasal sinuses? Is there a causal relationship?”

METHOD

Literature searching was performed with the keywords “nasal neurofibroma”, AND “nasal polyps”, AND “chronic rhinosinusitis” through database Google Scholar, PubMed, and hand searching/e-book.

The inclusion criteria were patients with neurofibroma in nasal cavity, chronic rhinosinusitis and nasal polyps.

RESULT

The search obtained 11 literatures which were published in the last 5 years, and found 7 articles relevant with the topics, but none reviewing the causal correlation between chronic rhinosinusitis with nasal polyps as an inflammatory process with neurofibroma on nasal cavity as a tumor growth.

DISCUSSION

CRS has a multifactorial etiology resulting from a dysfunctional interaction between various environmental factors and the host immune system.² The pathophysiology is likely to be more complex in older adults, as it would include age-related changes in biologic functions. Physiologically, several aging-related anatomical and functional change, such as decreased ciliary beat frequency, nasal mucosal atrophy, decreased nasal vasculature, and decreased nasal mucous secretion, may occur in the nasal mucosa. Decreased ciliary beat frequency and clearance, as well as thinning and drying of the mucosa, may lead to the stasis of thick mucus, followed by poor removal of external irritants.⁵

Older patients reported more loss of smell, but less rhinorrhea or nasal obstruction, than did younger patients. Clinical presentation of CRS in older patients is likely to be less typical than in younger patients. Aging related anatomical and physiological changes, may

underline the age-related differences in nasal symptom profiles.⁵ In this case, the patient was 64 years old, already considered as an elderly person. There was no complaint of rhinorrhea nor post nasal drip due to age-related changes in biologic functions.

Variation in paranasal sinus anatomy, as shown on CT-Scan is potential significance as it may contributing risks during surgery, or predispose to certain pathologic conditions.⁶ The most common anatomical variation was agger nasi 91.23%, followed by abnormal uncinat process 75.44%.⁷ Medial deviation was the most frequent variation of uncinat process observed,⁸ and variations of bullous middle turbinate in 30.2%.⁹ In this patient there was bullous at left middle turbinate seen in CT scan examination. This anatomic variation of the patient contributed as predisposing factor for CRS on the left nasal cavity.

Uncinat process is a key landmark in Functional Endoscopic Sinus Surgery, and is the first structure removed. Its anomalies are the most common anomaly found in the nasal cavity of patients with chronic sinusitis.⁸ When it is inserted into other nasal structures, it can lead to obstructions.¹⁰ Other anatomic variation in this patient was bilateral elongated (medially bent) uncinat process found on CT scan, and had been confirmed during operation. This condition led to patient's CRS condition.

Nasal obstruction is the main indication for septoplasty. Other indications are impairment of normal sinus drainage, sleep disorders, or headaches.¹¹ Septoplasty was not conducted to our patient during operation, because we assessed that the cause of nasal obstruction in the patient was not a septal deviation. This condition was confirmed through the follow up in ENT outpatient clinic, that patient did not complain of nasal obstruction after operation.

Chronic rhinosinusitis is divided into primary and secondary.² In this patient, there was a neurofibroma on the right side. But this condition did not cause CRS. While on both sides, there were anatomical variations (concha bullosa, medial bent uncinat process). Thus, this was classified as primary CRS.

Odontogenic sinusitis presents clinical features that are similar with non-odontogenic sinusitis, but is usually unilateral and not necessarily associated to ostium obstructions.¹² In this patient, sinusitis was bilateral. Patient also had an anatomical abnormality of medial bent uncinat process which was a factor of drainage disorders and obstruction in osteomeatal complex; and on CT scan, there was no visible root of premolars and molars in contact with maxillary sinus floor.

Main symptoms related to odontogenic sinusitis are: facial pain, toothache, nasal pain, nasal discharge, postnasal drip, nasal obstruction, discomfort of the face and gums, and bad odor.¹² Of all the symptoms mentioned, only nasal congestion was present in patient. This complaint could also due to a neurofibroma mass that had filled the right nostril. We concluded that the pathological condition in this patient was not odontogenic sinusitis.

Sinonasal lesions present a complex and interesting spectrum of clinical, radiologic, and histopathologic features. Non-neoplastic lesions are numerous, the morphologic variants of neoplasms are many, and most of them present as polypoid masses which are impossible to distinguish clinically.¹³ International multicenter studies showed the high risk that nasal polyposis can stimulate nasal and paranasal sinus malignancies.¹ In this patient, chief complaint was nasal congestion on the right side, while on the left nose, which had a polyp, there was no complaint of nasal congestion. In the right nasal cavity, there was an existence

of neurofibroma which was a benign lesion originating from neuron cells. While in the left nasal cavity there were polyps, which were lesions due to chronic inflammation of the mucosa, which was a non-neoplastic lesion. It had not been determined whether CRSwNP was a trigger for neurofibroma. The strongest possibility was that there were two different pathophysiological mechanisms in each lesion, and occurred in different tissues.

Complete local excision of neurofibroma is usually curative and the prognosis is excellent, if the tumor is completely removed.¹⁴ Neurofibromas are slowly growing benign tumors.¹⁵ Our patient had undergone complete tumor removal less than a month previously. Control of recurrence should be done for at least several years.

Malignant transformation of neurofibroma is rare unless the patient has neurofibromatosis,¹⁴ and it is extremely rare with only 5 cases reported in literatures till date.¹⁶

Neurofibromatosis was first described in 1882 by von Recklinghausen, and neurofibromatosis type 1 is its most common type. It is a syndrome with multiple neurofibromas, café-au-lait spots, and some bony changes like macrocephaly, pseudo-arthritis especially tibia, vertebral kyphosis, and bowing. The individual with at least two of the following criteria is identified as neurofibromatosis type 1:

1. There are 6 or more café-au-lait spots, which are light brown well circumscribed macules with regular border, that should be greater than 5 mm in youngsters and more than 15 mm in adults,
2. At least two neurofibromas of any form, or one plexiform neurofibroma,
3. Crow's sign, which are axillary and/or inguinal freckles,
4. Optic glioma,

5. At least two Lisch nodules (iris hamartomas),
6. Bone lesions like sphenoid dysplasia or thinning of the long bones' cortex, with or without pseudo-arthritis.¹⁵

Our patient did not have the symptoms criteria described above, there was also no family history of tumors. We assumed that there is very little, or almost no possibility of malignant transformation in our patients.

Neurofibroma is one of the most common benign tumors of peripheral nerve. In Otolaryngology Head and Neck Surgery, neurofibroma is more common in the throat, auditory nerve,¹⁷ and vestibular nerve.¹⁴ Primary neurofibroma in the nasal cavity is rare, accounting for only 2.75% of the benign tumors in the nose.¹⁷

Regarding zonal involvement, the literatures revealed that all areas of the nasal cavity and paranasal sinuses could be affected.¹ The anterior part of the nose (nasal vestibule, middle nasal meatus) is common, most of neurofibromas emerge from inferior turbinate or nasal septum, and it could involve the posterior nostril and pharynx.¹⁷ The origin of neurofibroma is considered to be perineural fibroblasts, which originates from neuroectodermal tissue.¹⁵ In this case, a neurofibroma stalk was found attached to the lateral part of the vestibule. The lateral wall of the vestibule is innervated by sensory nerve V1 and V2, branches of the trigeminal nerve.

The clinical symptoms of nasal neurofibroma are nonspecific, and could not be diagnosed by imaging examination alone. The diagnosis needs to be combined with pathological examination.¹⁷ In this patient, initially suspected to be a polypoid in both nasal cavities, but also suspected as tumor because the CT scan showed an approximate source of the mass was not from the middle meatus. Pathologic findings revealed a neurofibroma.

There are two types of neurofibromas clinically, subcutaneous and plexiform variety. The subcutaneous type develops at peripheral nerve endings, and termed as localized neurofibroma. It appears generally in late childhood or early adolescence, and constituted about 95% of cases. Plexiform variety develops in the body deeper areas near to the nerve roots, and is approximately consisted of 5% of cases. It generally appears during the first 2 years of life. Plexiform neurofibromas have the potential of malignant transformation to malignant peripheral nerve sheath tumors.¹⁵

Base on histological findings, plexiform neurofibromas are more aggressive subtype of neurofibroma, infiltrating through the soft tissue to grow multifocally along the length of the affected nerve. On the other hand, solitary neurofibromas are well-delineated, rubbery and firm lesions with a white and shiny appearance.¹⁸ In this patient, the tumor was only in one place, at the right nasal cavity originated from lateral vestibule. The tumor was solitary, well-delineated, firm lesion, and shiny appearance. There was no other tumor in patient. The type neurofibroma was localized neurofibroma.

All peripheral nerve-sheath tumors are believed to arise from Schwann cells. They often arise from sensory nerves, and are found in the head and neck, and the flexoral surface of the upper and lower extremities. However, they are rarely found in the nasal cavity and paranasal sinuses. In the nasal cavity and paranasal sinuses, the great majority of the peripheral nerve sheath tumors reported were Schwannomas,¹⁴ which have variable cellularity, including increased cellularity.⁴ Microscopic examination of neurofibroma showed interlacing bundles of elongated cells with wavy and dark-stained nuclei, wire-like strands of collagen, and myxoid stroma.¹⁹ In this patient, there was wavy nuclei but no variable of cellularity at pathologic finding.

This distinguished that in our patient was a neurofibroma and not a Schwannoma.

In conclusion, chronic rhinosinusitis with nasal polyps, along with neurofibroma on nasal cavity was a rare coincidence, and no correlation between lesions. Pathological examination is the gold standard in differentiating a definite diagnosis of neurofibromas and polyps.

REFERENCE

1. Nassrallah S, Neagoş CM, Mocan SL, Neagoş A. Evaluation of the incidence of inflammatory and tumor pathology of nose and nasal sinus region. *Rom J Morphol Embryol.* 2020;61(4):1295–300.
2. Fokkens WJ, Lund VJ, Hopkins C, Hellings PW, Kern R, Reitsma S, et al. European position paper on rhinosinusitis and nasal polyps 2020. *Off J Eur Int Rhinol Soc Confed Eur ORL-HNS.* 2020;58(2):1–400.
3. Tripathi AM, Singh YP. Clinical study of tumors of nose and paranasal sinuses-an observational study. *Int J Heal Clin Res.* 2020;3(7):30–7.
4. Bruce M, Wenig M. Neoplasms of the sinonasal tract. In: Bruce M, Wenig M, editor. *Atlas of Head and Neck Pathology.* 3rd ed. Philadelphia: Elsevier; 2016. p. 81–221.
5. Song WJ, Lee JH, Won HK, Bachert C. Chronic Rhinosinusitis with Nasal Polyps in Older Adults: Clinical Presentation, Pathophysiology, and Comorbidity. *Curr Allergy Asthma Rep.* 2019;19(10):1–8.
6. Dawood S. Normal anatomic variants of paranasal sinus region studied by computed tomography. *Zanco J Med Sci.* 2020;24(2):187–96.
7. Sonone J, Solanke P, Nagpure PS, Garg D, Puttevar M. Effect of Anatomical Variations of Osteomeatal Complex on Chronic Rhinosinusitis: A Propective Study. *Indian J Otolaryngol Head Neck Surg [Internet].* 2019 Nov 12;71(S3):2199–202
8. Tuli IP, Sengupta S, Munjal S, Kesari SP, Chakraborty S. Anatomical Variations of Uncinate Process Observed in Chronic Sinusitis. *Indian J Otolaryngol Head Neck*

- Surg. 2013;65(2):157–61.
9. Djorić I, Trivić A, Barna M, Milić I, Marković B, Valjarević S, et al. Multidetector CT of the Nasal Cavity and Paranasal Sinuses Variations in 73 Patients. *Indian J Otolaryngol Head Neck Surg.* 2021 Nov 8;(11).
 10. Baldea V, Cobzeanu MD, Mihalcea F, Service ENTA, Titulescu N. Anatomical variants of the uncinat process – CT scan imaging study. *Glob Acad J Med Sci.* 2021;2(7):69–73.
 11. van Egmond MMHT, Rovers MM, Hannink G, Hendriks CTM, van Heerbeek N. Septoplasty with or without concurrent turbinate surgery versus non-surgical management for nasal obstruction in adults with a deviated septum: a pragmatic, randomised controlled trial. *Lancet.* 2019;394(10195):314–21.
 12. Vidal F, Coutinho TM, Carvalho Ferreira D de, Souza RC de, Gonçalves LS. Odontogenic sinusitis: a comprehensive review. *Acta Odontol Scand.* 2017;75(8):623–33.
 13. Singh SG, Qureshi S, Jain L, Jadia S, Sharma S. Presentation of lesions of nose and paranasal sinuses at a tertiary care center in central India. *Indian J Otolaryngol Head Neck Surg.* 2018;70(2):284–9.
 14. I Katre M. Neurofibroma of nasal cavity and nasopharynx. *Adv Case Stud.* 2017;1(1):3–5.
 15. Raghuveer HP. Solitary, central neurofibroma of the mandible: a case report. *J Pierre Fauchard Acad.* 1994;8(3):107–9.
 16. Abraham B, Marickar YMF. Recurrent MPNST in Mosaic Localized Neurofibromatosis : A Rare Scenario – Review. *Sci Arch.* 2021;3(3):66–77.
 17. Shi X, Wang M, Li W. Nasal Neurofibroma with Cystic Degeneration : A Case. *Ann Clin Case Reports.* 2021;6(9):6–9.
 18. Min HJ, Kim KS. Removal of solitary neurofibroma of the external nose by intranasal approach. *Eur Ann Otorhinolaryngol Head Neck Dis.* 2017;134(4):273–5.
 19. Min HJ, Kim KS. Differential Diagnosis between Nasal Septal Schwannoma and Nasal Septal Neurofibroma. *J Craniofac Surg.* 2017;28(7):1780–3.