

**Case Report****Foreign body of fractured tracheal cannula  
in the bronchus after tracheostomy****Cavin Handoko, Mohammad Dwijo Murdiyo**

Otorhinolaryngology Department

Faculty of Medicine Universitas Brawijaya/dr. Saiful Anwar General Hospital, Malang

**ABSTRACT**

**Background:** Foreign body of fractured tracheal cannula in tracheobronchial tract is one of rare complication of tracheostomy. Symptoms appear in the form of respiratory distress and if not properly treated may threaten patient's life. **Objective:** To know the causative factors, management, and prevention of tracheal cannula foreign body in tracheobronchial tract. **Case report:** A 3-year-old boy reported with a foreign body of fractured tracheal cannula in his bronchus after tracheostomy. **Method:** Review of evidence-based literatures with keywords "foreign body" AND "tracheal cannula" on Google Scholar. **Result:** Extraction of foreign body of fractured tracheal cannula was performed by rigid bronchoscopy via the stoma, under general anesthesia, in all of the case reports in the literatures. After the procedure, the respiratory distress improved and patients could be discharged from the hospital. **Conclusion:** The definitive management of foreign body of fractured tracheal cannula in tracheobronchial tract by using rigid bronchoscopy transtracheostomy under general anesthesia is effective. Education and knowledge about post-tracheostomy care and follow up, are the keys to prevent such incidents.

**Keywords:** foreign body, tracheal cannula, bronchoscopy

**ABSTRAK**

**Latar belakang:** Benda asing patahan kanul trakea pada traktus trakeobronkial merupakan salah satu komplikasi trakeostomi yang sangat jarang ditemukan. Gejala yang muncul berupa gawat napas, dan jika tidak mendapat penanganan yang tepat dapat mengancam nyawa penderitanya. **Tujuan:** Untuk mengetahui faktor penyebab, tatalaksana dan pencegahan kasus benda asing kanul trakea pada traktus trakeobronkial. **Laporan kasus:** Melaporkan 1 kasus anak laki-laki berusia 3 tahun dengan benda asing patahan kanul trakea pada bronkus pasca trakeostomi. **Metode:** Telaah literatur berbasis bukti dengan kata kunci "foreign body" DAN "tracheal cannula" melalui Google Scholar. **Hasil:** Ekstraksi benda asing patahan kanul trakea dilakukan dengan bronkoskopi rigid melalui stoma dengan anestesi umum di seluruh laporan kasus. Setelah tindakan, gejala-gejala gawat napas mengalami perbaikan, dan pasien dapat dipulangkan dari rumah sakit. **Kesimpulan:** Tatalaksana definitif kasus benda asing patahan kanul trakea pada traktus trakeobronkial dengan menggunakan bronkoskopi rigid transtrakeostomi dengan anestesi umum dianggap efektif. Edukasi dan pengetahuan mengenai perawatan pasca trakeostomi dan kontrol rutin merupakan kunci dalam pencegahan kejadian seperti ini.

**Kata kunci:** benda asing, kanul trakea, bronkoskopi

**Correspondence address:** Cavin Handoko. Otorhinolaryngology Department, Faculty of Medicine Universitas Brawijaya/dr. Saiful Anwar General Hospital, Malang. Email: kodok\_metal@ymail.com

## INTRODUCTION

Tracheostomy is an open surgical procedure on the anterior part of the trachea by placing tracheal cannula temporarily or permanently according to its indications. Tracheostomy is a common procedure that usually performed as part of upper airway management in various medical circumstances by specialists such as surgeon, ENT specialist, and critical care unit specialist. Globally, the number of tracheostomies performed has increased due to uptrend in diseases such as laryngeal carcinoma, nasopharyngeal carcinoma, or paralysis of vocal cord which can result in upper airway obstruction.<sup>1,2</sup>

In the United States, tracheostomy was estimated to be 150 to 300 times performed per 100,000 hospitalized patients. Tracheostomy in children is about 7.5 per 100,000 patients. This procedure is safe and the mortality rate is less than 5%. Long-term use of tracheal cannula can increase the risk of complications. The complication of tracheostomy itself can be divided by the time after procedure. Early complications include bleeding, pneumothorax, obstruction, and infection of the wound; while late complications include granulation, scarring of the airway, and tracheoesophageal fistula.<sup>3</sup>

Foreign body of fractured tracheal cannula in tracheobronchial tract is one of the rare complications of tracheostomy. The most common symptom is mild respiratory distress, but if not treated properly could be life-threatening. In this case report, a foreign body in the tracheobronchial tract in the form of fractured tracheal cannula was presented. The purpose was to find the causal factors, management, and the prevention of tracheal cannula foreign body in tracheobronchial tract, in order to avoid such incident.

The knowledge about the management of foreign body of fractured tracheal cannula in tracheobronchial tract is important because of its rarity.

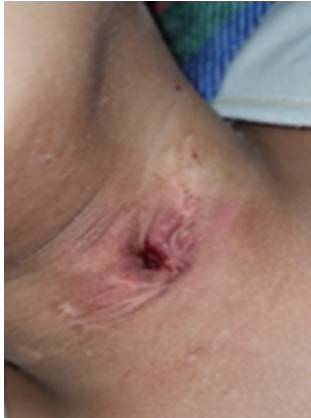## CASE REPORT

A 3-year-old boy was brought to the emergency room of Saiful Anwar Hospital, Malang, with complaints of shortness of breath for the last 2 hours. This complaint was reported by the patient's father after he saw the patient's hand tugging at the tracheal cannula. After the incident, the patient had repeated coughs, vomiting, and looked cramped.

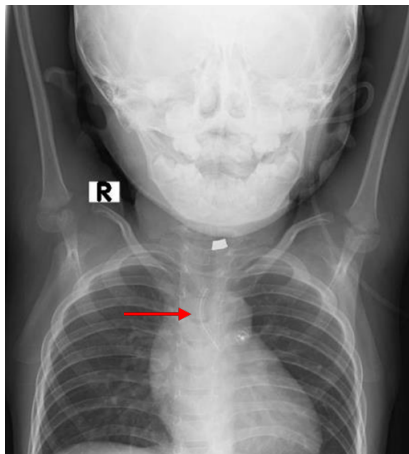
In the past, the patient had a history of congenital heart disease, and a heart valve closure surgery in August 2019. After the operation, patient experienced respiratory failure, and directly intubated, then treated at the Pediatric Intensive Care Unit (PICU) for 10 days. There, a tracheostomy was performed with an indication of prolonged intubation.

The fiberoptic laryngoscopy examination was carried out in November 2019 and the patient was diagnosed with subglottic stenosis Cotton Myers grade II. Afterwards, patient had several follow ups to the ENT clinic, although not routinely.

Upon arriving at the emergency room, the patient looked agitated with vital signs: pulse rate 112/minute, respiratory rate 30/minute, body temperature 36.8°C, and oxygen saturation 88% in room temperature. From the physical examination, stridor inspiration breathing sound was heard, also retractions were seen in the suprasternal, intercostal, and epigastric regions. From the head and neck examination, the post-tracheostomy stoma had scars and retracted inward (Figure 1). The air patency test on the stoma was negative. Immediately, an endotracheal tube (ETT) no. 3 was installed into the stoma, and subsequently the oxygen saturation increased to 95%. Thorax and cervical X-ray examination showed that there was a foreign body in the trachea located as high as vertebrae T2-T5 until main left bronchus (Figure 2).



**Figure 1.** Picture of the patient's stoma while in the emergency room

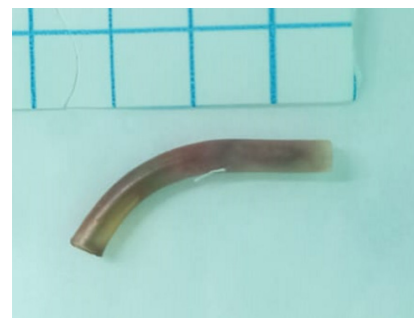

**Figure 2.** Chest X-ray showed a fractured tracheal cannula in the main left bronchus (arrow)

Bronchoscopy extraction procedure with general anesthesia was performed in the operating room. Pehacain infiltration was injected to tracheostomy peristoma, followed by incision under the stoma for about 2 cm. The incision was deepened until the trachea was visible. The tracheal stoma was then hooked open with silk thread 3.0 and forceps. Endotracheal tube was removed from the stoma, and then, bronchoscope no 3.5 was inserted into the trachea through the stoma until carina, left and right bronchi was seen. The evaluation was carried out by using telescope 0°, and the fractured tracheal cannula was spotted in the left bronchus. The extraction was performed using telescopic forceps; and then the evaluation was performed by using

a telescope, and no bleeding was found. The bronchoscope was then removed, and a new Portex Blue Line no 4 tracheal cannula was inserted into the stoma and fixated. From the inspection of the fractured tracheal cannula, it was found that the fractured site occurred on the boundary between the neck and the body of the cannula (Figure 3).

After the operation, the patient was confined in the ICU and then, transferred to a regular ward after his condition had stabilized. Antibiotic, mucolytic, analgesic, and nebulization were administered during the treatment. After improvement of general condition and symptoms, the patient was discharged from the hospital on the 7<sup>th</sup> day after the procedure. Education regarding the supervision, follow up and post-tracheostomy care was given to the parents.



**Figure 3.** The extracted fractured tracheal cannula

## METHOD

The literature search was conducted on March 19<sup>th</sup>, 2022 using Google Scholar search engine with keywords “foreign body” AND “tracheal cannula”. The inclusion criteria were publications in the last 15 years which relevance to the topic, and full manuscript was available. In the end, 10 literatures were obtained and used as the reference.

## RESULT

Moideen et al.<sup>2</sup> reported a case of 42 years old male patient, presented to the emergency

department with complaint of mild respiratory distress following aspiration of fractured metallic tracheal cannula. The patient had undergone tracheostomy 3 years previously due to bilateral abductor palsy following total thyroidectomy for thyroid papillary carcinoma. For the last 2 years, the patient never had follow-up, although he continued to use the cannula. The foreign body was taken out using bronchoscope forceps with the help of 0.4 mm nasal endoscope.

Piromchai et al.<sup>3</sup> reported a case of 14 years old boy with complaint of 2 weeks of intermittent cough due to foreign body of tracheal cannula. The patient had undergone tracheostomy for laryngeal stenosis following prolonged intubation after craniotomy for subdural hematoma evacuation 4 years before. The cannula had been used for one year. The patient then underwent bronchoscopy removal under general anesthesia, and the cannula was removed through the stoma.

Chehbouni et al.<sup>1</sup> reported a case of 70 years old male patient who underwent total laryngectomy 3 years previously, with prolonged placement of tracheostomy cannula at tracheostomy orifice. Patient was presented with progressive worsening of respiratory distress, fever, and desaturation for 4 days. After a thoracic CT scan, a tracheal cannula was found in the left tracheobronchial tract. Extraction procedure was performed with a rigid bronchoscope through tracheostomy orifice under general anesthesia.

Kraus et al.<sup>8</sup> found a case of 7 years old boy with CHARGE syndrome (coloboma, heart defects, atresia choanae, growth retardation, and ear abnormalities), with tracheostomy presented to the emergency room (ER) with vigorous coughing. Foreign body of tracheal cannula was found in the right mainstem bronchus after chest X-ray. By using rigid bronchoscope and forceps, the cannula was removed through the stoma.

Wu et al.<sup>9</sup> also reported a case of 14-month-old girl suffering Leigh's disease with progressive brain atrophy and ventilator dependent respiratory failure with tracheostomy. She was found in respiratory distress, 8 hours after her re-cannulation procedure. After chest X-ray, a broken cannula was seen in her left main bronchus, and an emergency bronchoscopy procedure was performed under general anesthesia to remove the fragment of tracheal cannula.

To prevent the occurrence of similar cases, Moideen et al.<sup>2</sup> and Piromchai et al.<sup>3</sup> had made several recommendations for post-tracheostomy patients such as:

1. Patient discharge plan and continuous support are important in post-tracheostomy patients;
2. Regular training and guidelines need to be established for general practitioners, community doctors, nurses, and paramedics to treat post-tracheostomy patients especially in remote areas;
3. Tracheal cannula should be checked for production defects or signs of looseness before insertion;
4. Regular follow up and replacement of tracheal cannula, twice per year (every 6 months);
5. Regular inspection of the cannula for looseness. The patient must have 2 spare inner tracheal cannulas at home;
6. The cleaning of the tracheal cannula carried out daily, every 2 days or more often, according to the volume of secretions produced.
7. Daily replacement of dressings on tracheostomy;
8. Weekly replacement of the cannula straps;
9. Clear education and information regarding tracheostomy care, to patients and caregivers;
10. In case of emergency, contact the hospital immediately, and a good referral system is important as an early detection.



## DISCUSSION

Tracheostomy complications can be divided into 3 types based on the time of post-tracheostomy; early, intermediate, and late complication. Early complications are complications that occur within 24 hours after the procedure. Intermediate complications are those that occur between 24 hours to 14 days after the procedure. Late complications are complications that occur after 14 days after the tracheostomy.<sup>4,5</sup> The case of foreign body of fractured tracheal cannula in tracheobronchial is an example of long-term post-tracheostomy complication.

Piromchai et al.<sup>3</sup> stated that 75% cases of fractured and aspiration of tracheal cannula were experienced by male. The majority of these cases was found more in adults than children. From 20 cases that had been reported, there were 7 cases which experienced by children. In this case report, the patient was a 3-year-old boy who was playing and tugging his tracheal cannula without parental supervision. This needs to be a special concern for parents who have children with tracheostomy, because their children can play on their tracheal cannula, especially during toddlerhood.<sup>2,8</sup>

Foreign body of fractured tracheal cannula was a quite rare case. Patient often experienced misdiagnosis when they came to the emergency room. In this case report, the patient experienced repeated coughs, dyspnea, and vomiting which were the symptoms of acute respiratory distress. The patient's father saw his son had a sudden dyspnea and broken tracheal cannula, then the patient was immediately taken to the emergency room within 2 hours. The quick response by his parents made this case diagnosable in less than 6 hours.

In some other studies, the duration of symptoms appeared until diagnosed was ranged from 1 to 132 months, with an average of 3 months.<sup>2,3</sup> In addition, the response from

medical personnel and residents when the patient arrived at the emergency room by installing a new endotracheal tube into his stoma, made the respiratory distress decreased rapidly. Most likely, the installation of the endotracheal tube made the upper airway obstruction reduced due to the fractured tracheal cannula being pushed from its initial position in the trachea into the left bronchus.

Doctors usually considered the symptoms that appeared in this case as asthma, chronic bronchitis or pneumonia until the thoracic X-ray was done. Thorax X-ray is helpful in determining the location and position of the foreign body. In some of the previous case reports, the fractured tracheal cannula was commonly found in the right main bronchus. The reason is because the right main bronchi are steeper and slightly wider than the left main bronchi. The diagnosis in this patient was also found by using thorax X-ray. The tracheal cannula was found to be at the level of distal part of the trachea, up till the proximal of the left main bronchus. The position and location of the fractured tracheal cannula in this case was somewhat different than most other case reports. However, there are several other case reports that found the foreign body in the left bronchus, carina, up to the posterior basal segment.<sup>2,8,9</sup>

Tracheal cannula is commonly made of metal, PVC, or silicone. Piromchai et al.<sup>3</sup> mentioned that from many incidences of fractured tracheal cannula observed, 14 of them used metal and only 3 cases used PVC cannula. This proved that PVC cannula tend to be more difficult to break. In this reported patient, the cannula that had been used was a Portex Blue Line which is a cannula with PVC based material. Many factors could cause the incidence of broken tracheal cannula, such as: cannula weakening due to boiling or sterilization, mechanical stress due to repeated use, tracheal stoma stenosis, aging of the cannula, production defects, reactions to tissues, disinfectant liquid, or the increase

production of bronchial secretions which are alkaline. In this patient, the most possible cause of fractured tracheal cannula was due to mechanical stress and aging of the tracheal cannula. Tracheostomy was first performed in August 2019, and then the patient never been re-cannulated, so that the tracheal cannula had been used for about 2 years at the time of this incident.<sup>1,2,3</sup>

In majority of the cases, the most common fracture location was the connection between the cannula and the neck plate, or the distal end of the cannula with fenestrated hole. The reason is, these locations are the weakest point of the cannula, so that it breaks very easily. The fractured site in this patient was found at the boundary between the body and the main connector neck plate, so that it was in accordance with the studies that had been carried out previously.<sup>1,3</sup>

Foreign body in tracheobronchial tract is a case that can be life-threatening and it requires an immediate emergency management. In this case report, the extraction of foreign body from the left bronchus was performed using rigid bronchoscope via stoma, under general anesthesia. The bronchoscope was inserted through the existing tracheal stoma, and the extraction was performed using forceps. After the tracheal cannula had been extracted, then re-cannulation was performed using a new tracheal cannula. After the procedure, the respiratory distress immediately improved, and the patient could be discharged 7 days after the procedure. The procedure and management of this patient were in accordance with the actions taken on various similar case reports.<sup>9</sup>

The majority case of fractured tracheal cannula aspiration was occurred in developing countries. Most likely this happened due to the continuous use of the same tracheal cannula for long periods, related with economic problem associated with cannula replacement fee, poor quality cannula, loss of follow-up, or poor tracheostomy care. Appropriate post-

tracheostomy care is the key in preventing this complication to happen.<sup>2</sup>

The case of foreign body fractured tracheal cannula in tracheobronchial tract is a rare long-term post tracheostomy complication which could be avoided. An appropriate post-tracheostomy care is the key to prevent the occurrence of such a case. The important post tracheostomy care consists of tube maintenance, cleaning of tracheal cannula and stoma, attention to the cuff, mobilizing the secret, and caring for other tracheostomy equipment. Regular follow up post tracheostomy and replacement of tracheal cannula twice per year (every 6 months) is a very important recommendation to avoid damage to the tracheal cannula.

## REFERENCE

1. Chehbouni M, Benhoummad O. Acute Respiratory Distress Revealing an Unrecognized Tracheostomy Cannula at the Bronchial Level in the Pandemic COVID Era. *Eur J Med Heal Sci.* 2021;3(3):72–4.
2. Moideen SP, Arun G, Mohan M, Afroze KH. Fractured Tracheostomy Tube - An Unusual Foreign Body in Tracheobronchial Tree. *Bengal J Otolaryngol Head Neck Surg.* 2017;47(10):788–9.
3. Pirochchai P, Lertchanaruengrit P, Vatanasapt P, Ratanaanekchai T, Thanaviratananich S. Fractured metallic tracheostomy tube in a child: a case report and review of the literature. *J Med Case Rep.* 2010;4:234.
4. Walvekar RR, Myers EN. Technique and Complications of Tracheostomy in Adults. In: Myers EN, Johnson JT, editors. *Tracheotomy: Airway Management, Communication and Swallowing.* 2<sup>nd</sup> ed. San Diego: Plural Publishing; 2008. p. 35-67.
5. Abid O, Hakim A, Akram N. Complications after surgical tracheotomy. *J Med Sci.* 2013; 21(4):165–7.
6. Vallamkondu V, Visnathan V. Clinical Review of Adult Tracheotomy. *J Periop Pract.* 2011;21(5):172-6.

7. Morris L, Afifi MS. Tracheostomies: the complete guide. Springer Publishing Company; 2010 Feb 19.
8. Kraus M, Le Roger M. Aspiration of a fractured tracheostomy cannula in a pediatric patient. *Can J Anesth.* 2016;63(12):1376–7.
9. Wu CT, Lin JJ, Yeh R. Migration of fragmented tracheotomy tube into left main bronchus. *Int J Pediatr Otorhinolaryngol Extra.* 2007;2(1):58–60.
10. Hess DR, Altobelli NP. Tracheotomy Tubes Discussion. *Respir Care*, 2014;59(6):956-73.