

Case report**Management of foreign body a fish in orohypopharynx****Ade Asyari, Esmaralda Nurul Amanya**Department of Otorhinolaryngology Head and Neck Surgery, Faculty of Medicine,
Andalas University / Dr. M. Djamil General Hospital,
Padang**ABSTRACT**

Background: Foreign bodies ingestion in children is very common, and most events occur in children between 6 months and 3 years. Alive fish foreign body is a rare case that could lead into upper airway obstruction. The diagnosis was based on history, clinical and radiography examinations. **Purpose:** To report a case and the management of an alive fish as foreign body in orohypopharynx. **Case report:** A 5 years old boy was brought with alive fish as foreign body in the orohypopharynx. The management was foreign body extraction and followed by rigid esophagoscopy procedure. **Clinical question:** What is the management of a fish as foreign body in orohypopharynx? **Method:** Evidence based literature study of foreign body a fish in orohypopharynx. **Result:** Management of foreign body a fish in orohypopharynx by extraction and rigid esophagoscopy gave a good result. **Conclusion:** Precise diagnosis and treatment could prevent any complications caused by foreign body a fish in orohypopharynx. It is important to secure the airway, making sure there is no any part of the foreign body left and evaluating the esophagus mucosa. If there is any sign of mucosa injury, nasogastric tube applied until the injury healed.

Keywords: foreign body a fish, orohypopharynx, esophagoscopy**ABSTRAK**

Latar belakang: Tertelan benda asing pada anak sangat umum, sering terjadi, dan paling banyak terjadi pada usia 6 bulan hingga 3 tahun. Benda asing ikan hidup merupakan kasus yang jarang dan dapat menyebabkan sumbatan jalan nafas atas. Diagnosis berdasarkan anamnesis, pemeriksaan fisik dan radiologi. **Tujuan:** Melaporkan sebuah kasus tatalaksana benda asing ikan hidup pada orohipofaring. **Laporan kasus:** Dilaporkan satu kasus seorang anak laki-laki berusia 5 tahun dengan benda asing ikan hidup di orohipofaring. Tatalaksana pada kasus ini ialah ekstraksi benda asing dan esofagoskopi kaku. **Pertanyaan klinis:** Bagaimana tatalaksana kasus benda asing ikan di orohipofaring? **Metode:** Berbasis bukti mengenai benda asing ikan di orohipofaring melalui database Cochrane library, Pubmed Medline, dan pencarian manual. **Hasil:** Tatalaksana benda asing ikan di orohipofaring dengan ekstraksi benda asing dan esofagoskopi kaku memberikan hasil yang baik. **Kesimpulan:** Diagnosis dan tatalaksana yang tepat dapat menghindari terjadinya komplikasi pada kasus benda asing ikan di orohipofaring. Penting untuk menjaga patensi jalan nafas, memastikan tidak ada bagian dari benda asing yang tertinggal serta mengevaluasi mukosa esofagus. Jika terdapat trauma pada mukosa, pemasangan nasogastric tube dapat dilakukan hingga terjadi penyembuhan luka.

Kata kunci: benda asing ikan, orohipofaring, esofagoskopi**Correspondence address:** Ade Asyari, Department of Otorhinolaryngology Head and Neck Surgery, Faculty of Medicine, Andalas University / Dr. M. Djamil General Hospital, Padang.
Email: adeasyari2@gmail.com

INTRODUCTION

A variety of foreign bodies lodging in upper aerodigestive tract is common in otorhinolaryngology practices.¹ These may get lodged in tonsil, base of tongue, pyriform fossae, and esophagus or sometimes in the larynx or lower down in the respiratory tract leading to medical/surgical emergencies which are often challenging.²

Foreign body ingestion in children is very common, and mostly occur in children between 6 months and 3 years of age.³ There is no requirement for predisposing anatomic or pathological condition. However, that in addition to younger persons, those at highest risk include edentulous, incarcerated, and psychiatric patients. In pediatric series, endoscopy, including esophagoscopy, laryngoscopy, tends to be successful in removing the foreign body in nearly all cases.⁴

Fish bone as foreign body in the throat is very common in otorhinolaryngology practice. But alive fish in orohypopharynx is very rare. Ingested fish could get impacted or migrated to esophagus, nasopharynx, or airway.⁵ The diagnosis is based on history, clinical and radiography examination.²

Foreign body ingestion patients presented with wide range of symptoms and sign depending upon age, nature of foreign body, anatomical site of lodgment, and length of time since ingestion.^{6,7} Older children and nonimpaired adults may identify the ingestion and localize discomfort. Frequently, symptoms occur well after the patient ingest the foreign body. Patients may present with choking, refusal to eat, vomiting, drooling, blood-stained, or respiratory distress.⁸ A useful history is usually available from the patient or caregivers.⁴

The main objectives of initial evaluation of patients with suspected foreign body ingestion include ruling out airway compromise, confirming the presence and location of the foreign bodies, and ruling out

complications. A thorough clinical history can provide valuable information about the circumstances under which the ingestion occurred, the type of foreign bodies, the time elapsed since ingestion, and the presence of underlying disorders, such as gastroesophageal reflux disease, esophageal motor disorders, previous surgery, intoxication, and psychiatric disorders. Oropharyngeal foreign bodies are usually identified by direct visualization. Unfortunately, most foreign bodies will pass beyond the level of direct visualization, thus requiring indirect laryngoscopy or fiberoptic nasopharyngoscopy.⁹ Subcutaneous emphysema found by neck palpation indicates probable esophageal perforation. Drooling and inability to handle secretions are secondary indicators of esophageal impaction; wheezing can occur if there is airway compression.⁴

Radiography can confirm the location, size, shape, and number of ingested foreign bodies and help exclude aspirated objects. However, fish or chicken bones, wood, plastic, glass, and thin metal objects are not readily seen.⁸ Radiography contributes to diagnosis and management in about half of foreign body ingestion cases. The primary utility of plain radiography lies in detection of radiopaque objects, although lateral neck x-ray films identify indirect signs (e.g., soft tissue swelling) in most patients with proximal aerodigestive tract foreign body.⁴ For all suspected case of foreign body ingestion, lateral and anteroposterior radiography of neck should be taken.¹⁰

Multidetector computerized tomography (CT) is superior to plain radiography for detecting pharyngoesophageal foreign bodies. It is indicated when plain radiography are negative despite strong clinical suspicion of a foreign body.⁹ CT scans with coronal and sagittal reconstructions are useful in identifying foreign bodies or more completely characterizing objects seen on plain films. CT also can assist with identification of complications. Also, CT may be used

in patients with positive plain films and negative endoscopy to search for objects that have migrated from the intraluminal to extraluminal space.⁴

An impacted foreign body in the oropharynx should be immediately removed as the chance of spontaneous passage is less likely. A delay in the procedure causes edema of the mucosa which lodges the object more firmly, making later manipulation extremely difficult. More serious and potential life threatening complications include esophageal perforation, mediastinitis, cervical or mediastinal abscess, emphysema, esophageal-tracheal fistula and septic complications.¹¹ Complications including respiratory obstruction may occur with large foreign body. Retropharyngeal abscess formation may occur as late presentation especially in sharp objects. Sharp objects may cause perforation manifesting as pneumomediastinum.¹²

Initial management includes assessment of the patient's ventilatory status and an airway evaluation. Pediatric endoscopy also often uses general anesthesia and endotracheal intubation. The need for and timing of an intervention for foreign body ingestion depend on the patient age and clinical condition: the size, shape, content, anatomic location of the ingested object(s), and the time since ingestion.⁸ Most ingested foreign bodies are best treated with flexible endoscopes. However, rigid esophagoscopy maybe helpful for proximal foreign bodies impacted at the level of the upper esophageal sphincter or hypopharyngeal region and may allow protection of the airway.⁸

We would like to report a case of alive fish foreign body in orohypopharynx which was extracted and followed by rigid esophagoscopy procedure.

CASE REPORT

A five years old boy was brought to M. Djamil Hospital's emergency room on May 10th 2019 with chief complaint an alive fish accidentally stucked in his throat since 2 hours before admission. Previously the patient had caught a fish at a rice field and tried biting the fish while trying to catch another one. Suddenly, the fish jumped in and stucked in his throat. There was pain and difficulty in swallowing. There was saliva mixed with blood drooling. There was no hoarseness. There was no difficulty in breathing, choking, coughing nor cyanosis.

On physical examination, the general condition was moderately ill, compos mentis cooperative, pulse rate was 105x/minute, respiration rate 24x/minute, temperature 37°C, SpO₂ 98%. On thorax examination, thorax movement was symmetric, no retraction, nor abnormal breathing sound, stridor, or wheezing. Otoscopy and rhinoscopy examinations were within normal limit. In oral cavity, there was saliva mixed with blood, and a motionless fish tail could be seen filled the oropharynx. The throat was difficult to evaluate.

Patient was diagnosed with 'a fish' foreign body in orohypopharynx based on anamnesis and physical examination. Blood test was performed to this patient and the result was within normal limit. On plain AP and lateral x-ray examination there was a foreign body with a fish appearance at oropharynx to cervical-V projection (Figure 2). Patient was diagnosed with 'a fish' foreign body in orohypopharynx and was prepared to undergo foreign body extraction and rigid esophagoscopy procedure in general anesthesia. Patient was also be prepared for tracheostomy in case the intubation failed.

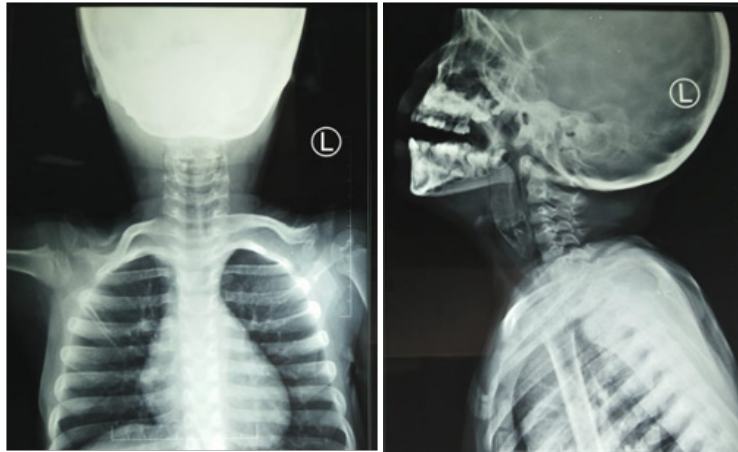


Figure 1. Anteroposterior and lateral cervical x-ray

On May 10th 2019, foreign body extraction and diagnostic and therapeutic esophagoscopy procedure were performed. Patient was laid in supine position in general anesthesia. Aseptic and antiseptic procedure was performed, and the anesthesiologist evaluated the airway by laryngoscope. The foreign body was seen in the orohypopharynx and did not blocked the larynx, so endotracheal intubation was successfully implemented. Then, Davis gag was inserted, followed by evaluation with 0° scope which showed the fish tail at oropharynx and immobile. Then, the fish was extracted by cutting down the tail by scissor and extracted with Allis clamp. The remaining part of the fish was extracted carefully using Allis clamp and forceps, and the debris of fish scales and skin were cleaned up until there was no foreign body left. Upon evaluation there was excoriations at pharyngeal arch and posterior pharyngeal wall and the Davis gag was removed.

Next, esophagoscopy was performed to evaluate the esophagus using rigid esophagoscope (size 8mm x 12mm x 30cm). The patient's head was in flexion position. Esophagoscope was inserted in the right side of the tongue until uvula and posterior pharyngeal wall were visible, then going through the arytenoid, pyriformis sinus until the introitus of esophagus was seen.

The esophagoscope going down up in the esophagus till 15 cm from incisivus and there was laceration and fish scales at 10-12 cm from incisivus. The remaining part of the fish was irrigated with saline solution and suctioned until there was no foreign body left. Evaluation of the laryngeal area found no foreign body, nor edema, laceration, and excoriation, then the esophagoscope was removed. Afterwards nasogastric tube (NGT) number 14 was inserted.

The patient was hospitalized in ORL-HNS Departement wards and given therapy Ceftriaxone injection 2x500 mg, Dexamethasone injection 3x1,5mg, Ranitidine injection 2x25 mg, Ketorolac 7,5 mg in 500 cc Ringer lactate 8 hours/kolf. Post operation instructions were monitoring vital sign, bleeding from the mouth, and sign of airway obstruction. Diet liquid meal via NGT.

One day after surgery, May 11th 2019, patient still felt pain while swallowing and had cough episodes, but there were no bloody saliva, difficulty in breathing, fever, nor hoarseness. On physical examination, in the left nasal cavity there was NGT and no blood. The pharyngeal arch was symmetric and hyperemic. There were hyperemic and NGT seen at posterior pharyngeal wall area. There was no active bleeding (Figure 3). The medications were continued.

Four day after surgery, May 14th 2019, there was cough, there was no pain in the throat, no bloody saliva, no difficulty in breathing, no fever, and no hoarseness. On physical examination, the pharyngeal arch and posterior pharyngeal wall was minimally hyperemic. (Figure 4). The patient took swallowing test and there was no choking and coughing. The NGT was removed. Patient was discharged and given therapy

Cefixime syrup 100 mg/5 ml 2x 3,75 ml and N-acetylsisteine syrup 100 mg/5ml 3x5 ml orally.

Patient was suggested to control to ORL-HNS outpatient clinic Dr. M. Djamil Hospital Padang a week later but did not come. We did a follow up via telephone 2 weeks after the incident there were no pain while swallowing, choking while eating and drinking, coughing or hoarseness.



Figure 2. Foreign body a fish after extraction

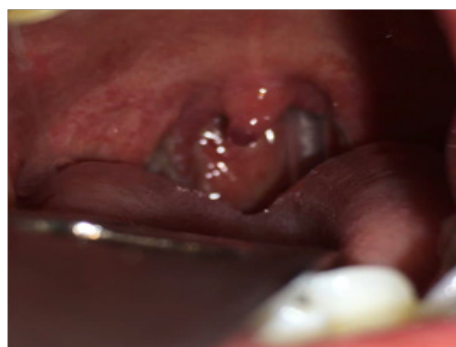

Figure 3. Oropharyngeal examination 1st day after surgery

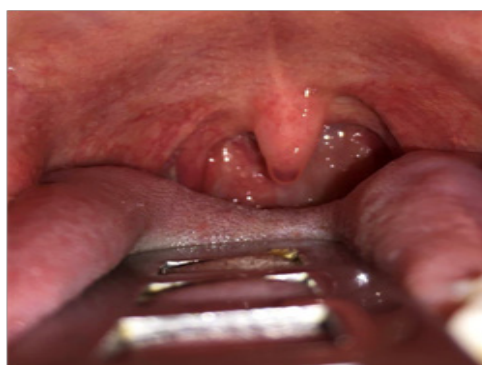

Figure 4. Oropharyngeal examination 4th day after surgery

CLINICAL QUESTION

What is the appropriate management of a fish foreign body in orohypopharynx?

REVIEW METHOD

Literature search was performed with keywords “a fish foreign body” AND “orohypopharynx” AND “esophagoscopy” through database Cochrane library, Pubmed Medline, and hand searching.

The selection of literatures was based on inclusion criteria, which were: 1) a fish foreign body in orohypopharynx patients. 2) extraction foreign body and esophagoscopy procedure. The exclusion criterion was fish foreign body in orohypopharynx management by open surgery. The critical review was conducted on 35 literatures, before applying inclusion and exclusion criteria.

RESULT

The literature search obtained scientific publications which were released in the last 10 years, relevant with the topics and the complete academic scripts were available.

Dwivedi¹⁰ stated that investigating patients with suspected foreign body ingestion should start with the ABC approach for resuscitation to ensure that the airway is safe. If the airway is at risk, patient might need emergency intubation with or without tracheostomy to secure the airway.

In the same cases, Asyari¹³ and Khatua¹⁴ successfully removed the fish in the throat using Magill's forceps. On another hand, Joson¹¹, in a same case, removed the fish using Mixter right-angle forceps. After extracting the foreign body, esophagoscopy evaluation should be carried out to see whether there is any remaining foreign body like fish scales and the possibility of damage to the esophageal mucosa. Postremoval endoscopic examination could rule out any residue of fish and mucosal injury.¹⁵

DISCUSSION

Reported a case of a live fish foreign body at orohypopharynx in a 5 years old boy. This was a rare case, in ORL-HNS Department of Dr. M. Djamil Padang Hospital recorded only 5 such cases from 2008-2018 which were treated by extraction of the foreign body under general anesthesia with and without tracheostomy. Ali and Metha, quoted by Benoist¹⁶, reviewed 75 cases of live fish aspiration reported in the scientific literature between 1967 and 2015. Of these fishes, 56 ended up in the upper airway and hypopharynx. Pradhan et al.⁵ stated that there was no age group from live fish ingestion. Starting from 7 months, it is reported up till 65 years of age. The enhanced risk of aspiration in this age group is attributed to inherent anatomic and physiologic characteristics like

inadequately developed posterior dentition, immature neuromuscular mechanisms of deglutition, airway protection and the ubiquitous tendency of putting objects into the mouth.¹⁷

On anamnesis, it was found that patient was catching a fish and tried biting the fish. Suddenly the fish jumped and stuck in his throat. The habit of biting fish in mouth while trying to catch another in the fishing net is the most common cause of live fish ingestion in literature.¹⁴

Seen from another side, Pradhan⁵ stated in his paper that the causes of ingestion of live fish are interesting. Mostly, fishermen bite one fish and make their hands free to catch another, the struggling fish escapes and gets stuck in the oropharynx. Some people swallow live fish as medicine for treatment of asthma, which accidentally gets embedded in the throat. The rarest cause is while taking bath, live fish accidentally enter into the oropharynx.

Common sites of impaction include the tonsils, base of the tongue, pyriform fossae and the cricopharynx. However, a bigger foreign body in the throat may block both the trachea and esophagus and result in death. In most cases of foreign bodies in children, diagnosis maybe difficult because a clear history cannot be obtained due to the lack of characteristic clinical features and radiography finding.¹¹ If the size of the fish is big, it can cause suffocation, choking and death before reaching the hospital. If the size of fish is small and fins and scales are firmly attached to the oropharynx or hypopharynx causing no immediate effect, but demands hospital management.¹⁴ It was also stated that sometimes, while removing the fish from the oropharynx, it may slip and fall on the larynx causing obstruction. So it is always tricky to remove this type of foreign body, though the tail is visible.⁵ During attempts of manual removal, the fish may slip and drop down into trachea and bronchus.¹ In our patient, on

oral examination revealed there was a fish tail fulfilled the oropharynx. Radiography examination will indicate the exact position of the fish in the aerodigestive tract.⁵ Kanne¹⁸ also stated that radiography has the benefit of evaluating the deeper soft tissue and revealing potential complication. Based on plain anteroposterior and lateral x-ray examination there was foreign body a fish appearance at oropharynx to cervical-V projection.

This patient was planned to undergo foreign body extraction and followed by rigid esophagoscopy procedure in general anesthesia. Patient was also prepared for tracheostomy if the intubation failed. The treatment of choice was endoscopic removal of the foreign body, which was successful with minimal complications for the patient. The surgical treatment should be performed when endoscopic management is not possible to solve the problem, or if there is impairment of progression in the gastrointestinal tract or complications such as perforation, obstruction and bleeding.¹⁹

In this patient, tracheostomy was prepared if intubation failed. But at the time, when evaluated by anesthesiologist with laryngoscope, the patient's larynx was able to be evaluated and intubation could be performed. Tang²⁰ reported one case of fish in the throat that had to be tracheostomized because the fish impaction was causing near total upper airway obstruction and inhibiting intubation for proper anaesthesia. The patient was dyspnoeic and unable to lie supine. Tracheostomy preparation is an important procedure to reduce the risk of morbidity and mortality if endotracheal intubation can not be performed. Meanwhile, according to Parida¹⁵ tracheostomy procedure is required if upper airway obstruction is present. A similar case was reported at Dr. M. Djamil Padang Hospital on 2010 with upper airway obstruction grade 2 caused by fish foreign body at hypopharynx, and tracheostomy was performed prior to foreign body extraction

under general anesthesia. Another case report on 2016 at Dr. M. Djamil Padang Hospital of a patient with a fish foreign body in orohypopharynx and foreign body extraction was performed under general anesthesia without tracheostomy because there was no symptom nor sign of upper airway obstruction such as difficulty in breathing, cyanosis and stridor.¹³

Management of this case was tearing down the fish tail by scissor and extraction with Allis clamp. The remaining part of the fish was extracted carefully using Allis clamp and forceps. Tearing down the part of the tail was performed to reduce the risk of injury caused by stucked sharp parts of the fish while removing it. Pradhan⁵ also reported a successful maneuver using Allis clamp to extract a fish in the throat. In our case, after the foreign body extraction, there could be seen excoriations at pharyngeal arch and posterior pharyngeal wall. Next, rigid esophagoscopy was performed and showed laceration at 10-12 cm from incisivus and there were some fish scales, which was then irrigated using saline solution and suctioned until no foreign body left. Asyari¹³ also stated that evaluation into the esophagus needs to be performed to see whether there is still remaining foreign body like fish scales, and the possibility of damage to the esophageal mucosa.

After extraction, it was found that the foreign body was a 'climbing perch' or *Anabas testudienus*, locally known as *ikan puyu* or *ikan betok*. It is a bony fish, that has a labyrinth organ that can allow it to survive on land for seven hours.²¹ The gills are covered with bony opercula with 6 to 8 tooth like processes.¹⁴ Climbing perch has very sharp fins over the dorsal and ventral surfaces with the help of which they can crawl over the ground and climb trees. When ingested, they can cause severe trauma to the aerodigestive tract. It may lead to bleeding and respiratory distress. If it is lodged over the larynx, the patient may not manage to reach the hospital.⁵

After operation, NGT was applied for 4 days to the patient because there was laceration at 10-12 cm from incisivus. In a case of foreign body live fish in oropharynx in India, patient with laceration caused by the live fish was also placed NGT until the laceration healed.⁵ NGT was placed to allow wound healing and to avoid any infection or food bolus that could disturb mucosal repair.²⁰

In our patient there was there was excoriations at pharyngeal arch, posterior pharyngeal wall, and laceration at 10-12 cm from incisivus. It is commonly happen after foreign body ingestion but usually improve in a few days.⁹ Another complications due to live fish in aerodigestive tract include perforation of pharynx, mediastinitis, deep lacerations leading to secondary infection, remnant of sharp fins in the tissue, and death because of total obstruction. Sometimes, the lacerations may lead to retropharyngeal and parapharyngeal abscess which may present later and should be managed promptly.⁵ In our patient, there was no any sign or symptoms of these complications.

A live fish foreign body in orohypopharynx is a rare case. Accurate diagnosis and treatment could prevent the occurrence of complications. It is important to secure the airway passage. The foreign body extraction could be performed without tracheostomy if there were no sign of upper airway obstruction and the foreign body did not block the airway for intubation. The extraction of the foreign body should be carried out carefully, making sure there is no any part of the foreign body left and followed by esophagoscopy evaluation. If there is any sign of mucosa injury, nasogastric tube should be applied until the wound healed.

REFERENCES

1. Sangma R, Ranjan K. An Unusual Case of Foreign Body Whole Fish in Throat - A Case Report. *IOSR J Dent Med Sci.* 2015;14(6):57-9.
2. Sharma RC, Dogra SS, Mahajan VK. Oro-Pharyngo-Laryngeal Foreign Bodies : Some Interesting Cases. *200 Indian J Otolaryngol Head Neck Surg.* 2012; 64(June): 197-200.
3. Lee JH. Foreign Body Ingestion in Children. *Korean Soc Gastrointest Endosc.* 2018: 129-36.
4. Thomas SH, Goodloe JM. Foreign Bodies. In: Rosen's Emergency Medicine. 8th ed. Philadelphia: Elsevier; 2014:767-84.
5. Pradhan S, Gupta S, Dash AP, Mohanty J, Rana AK. A Rare Case of Live Fish in Oropharynx and Its Management. *Otorhinolaryngol Clin.* 2018; 10(August):73-5.
6. Sinha S, Kumar S. Upper gastrointestinal tract foreign body in children India. *Int Surg J.* 2016; 3(4): 2046-9.
7. Ag A, An U, Me O, et al. Unique Foreign Bodies in the Aerodigestive Tract. *J Nurs Healthc.* 2017; 2(2): 4-7.
8. Ikenberry SO, Jue TL, Michelle A. Anderson, et al. Management of ingested foreign bodies and food impactions. *Gastrointest Endosc.* 2011; 73: 1085-91.
9. Senar AC, Dinu LE, Artigas JM, Larrosa R, Angulo E. Foreign Bodies on Lateral Neck Radiographs in Adults : Imaging Findings and Common Pitfalls. *Radiographics.* 2017; 37: 323-45.
10. Dwivedi RC, Kenway B, Haribaskaran K, Jani P. Lamb ingestion and odynophagia. *BMJ.* 2016; 5506 (November): 2-5.
11. Joson SN, Almazan NA, Cruz MGY. An Impacted Live Fish in the Oropharynx of an 8-Year-Old Child. *Philipp J Otolaryngol Neck Surg.* 2017; 32(1): 44-6.
12. Das J, Ghosh D, Saha J, Basu SK. An Asymptomatic Pointed Foreign Body in the Hypopharynx - A Rare Case Report. *Bengal J Otolaryngol Head Neck Surg.* 2016; 24(2): 1-6.
13. Asyari A, Novialdi N, Azizah N. Foreign body a fish in orohypopharynx with complication vocal cord paralysis. *Maj Kedokt Andalas.* 2018; 41(1): 32-9.

14. Khatua RK. Fish in Hypopharynx : A Rare Case Report. 2015; 7 (August): 81-2.
15. Parida PK, Surianarayanan G. Accidental Entry of Fish into Throat While Bathing in a Pond Case Report Accidental Entry of Fish into Throat While Bathing in a Pond. 2013.
16. Benoist LBL, Hoven B Van Der, Vries AC De, et al. A jackass and a fish : A case of life-threatening intentional ingestion of a live pet catfish (*Corydoras aeneus*). Acta Oto-Laryngologica Case Reports. 2019; 4(1): 1-4.
17. Gunasena S, Lanka S. Unusual Foreign body “ Live Fish .” Indian Pediatr. 2013: 524.
18. Kanne JP, Mann FA. Pharyngeal Perforation from an Impacted Fish. 2004; (March): 359728.
19. Coêlho GR, Torres SM, Almeida DC De, Moreira LM. Surgical Treatment of Fish Impacted in the Upper Esophagus. ABCD Arq Bras Cir Dig. 2016; 29: 66-7.
20. Tang ML, Ching LS, Brito-Mutunayagam S, Revadi G. Fish in throat: An unusual foreign body. Med J Malaysia. 2013; 68(6): 469-70.
21. Ernawati Y, Kamal MM, Yolanda A. Biologi Reproduksi Ikan Betok di Rawa Banjiran Sungai Mahakam, Kalimantan Timur. J Iktiologi Indones. 2009; 9(2): 113-27.