

**Case Report****Coalescent mastoiditis as a complication of acute otitis media**

**Ratna D. Restuti, Harim Priyono, Dora A Marpaung, Ayu Astria Sriyana,  
Rangga Rayendra Saleh**

Otology Division, Department of Otorhinolaryngology Head and Neck Surgery,  
Faculty of Medicine Universitas Indonesia / Dr. Cipto Mangunkusumo Hospital,  
Jakarta

**ABSTRACT**

**Background:** Acute otitis media (AOM) is one of the most common infections in children. AOM disease can lead to complications such as coalescent mastoiditis. Mastoidectomy surgery in cases of coalescent mastoiditis in children is still a debate. **Purpose:** To convey the management of coalescent mastoiditis in pediatric patients as complication of AOM using an evidence-based literature search. **Case Report:** A 10-month old patient with a diagnosis of AOM and coalescent mastoiditis, who was given antibiotic therapy and abscess drainage incision. **Clinical question:** In a child with coalescent mastoiditis as a complication of otitis media, could the disease be cured with intravena antibiotic therapy only without mastoidectomy operation? **Review methods:** Evidence-based literature searches through Pubmed, Proquest and Cochrane were performed using the keywords mastoidectomy, antibiotics and coalescent mastoiditis. **Result:** The search resulted in 277 literatures, and 12 were relevant with the case, and two journals stating that in cases of uncomplicated coalescent mastoiditis, mastoidectomy operation could be postponed and intravenous antibiotic could be administered with monitoring of the patient's condition for 48 hours. **Conclusion:** Intravenous antibiotic is the primary therapy in cases of coalescence mastoiditis accompanied by clinical monitoring for 48 hours. Additional mastoidectomy and other surgeries were performed in cases of clinical deterioration after intravenous antibiotic therapy, and in cases of intratemporal or intracranial complications.

**Keywords:** coalescent mastoiditis, acute otitis media, antibiotic, mastoidectomy

**ABSTRAK**

**Latar belakang:** Otitis Media Akut (OMA) merupakan salah satu infeksi yang sering ditemukan pada anak. Penyakit OMA dapat mengakibatkan komplikasi seperti mastoiditis koalesens. Operasi telinga mastoidektomi untuk kasus mastoiditis koalesens anak masih merupakan perdebatan sampai saat ini. **Tujuan:** Mengulas tatalaksana mastoiditis koalesens akibat OMA pada pasien anak menggunakan pencarian literatur berbasis bukti. **Laporan Kasus:** Seorang pasien umur 10 bulan dengan OMA dan komplikasi mastoiditis koalesens. Dilakukan tatalaksana terapi antibiotik dan insisi drainase abses. **Pertanyaan klinis:** Pada kasus anak kecil dengan mastoiditis koalesens sebagai komplikasi otitis media akut, apakah penyakit ini dapat disembuhkan hanya dengan pemberian terapi antibiotik intravena tanpa operasi mastoidektomi? **Telaah literatur:** Telaah berbasis bukti dilakukan melalui Pubmed, Proquest dan Cochrane, dengan menggunakan kata kunci mastoidektomi, antibiotik dan mastoiditis koalesens. **Hasil:** Telaah berbasis bukti menghasilkan 277 literatur, 12 diantaranya relevan dengan kasus, dan dua literatur menyatakan bahwa pada kasus mastoiditis koalesens tanpa komplikasi, mastoidektomi bisa ditunda dan pemberian antibiotik intravena bisa diberikan dengan pemantauan kondisi pasien selama 48 jam. **Kesimpulan:** Pemberian antibiotik intravena merupakan terapi utama pada kasus mastoiditis koalesens disertai pemantauan klinis selama 48 jam. Terapi lanjutan berupa mastoidektomi dan operasi lainnya dilakukan pada kasus dengan perburukan klinis sesudah terapi antibiotik intravena, dan pada kasus komplikasi intratemporal atau intrakranial.

**Kata kunci:** *mastoiditis koalesens, otitis media akut, antibiotik, mastoidektomi*

**Correspondence address:** Ratna D Restuti. Department of Otolaryngology Head and Neck Surgery, Faculty of Medicine Universitas Indonesia / Dr. Cipto Mangunkusumo Hospital, Jl. Diponegoro No.71, Jakarta. Email: ratna.drest@gmail.com.

## INTRODUCTION

Acute otitis media (AOM) is one of the most common childhood clinical problems. AOM is generally self-limiting, with most children experiencing symptom resolution within a few days. In general it has a benign natural history, but AOM could progress to a number of severe complications such as acute mastoiditis, sigmoid sinus thrombosis, or intracranial abscess. Before the antibiotic era, acute mastoiditis was the most common side effect of OMA requiring hospitalization among infants and children. Antibiotic therapy has decreased the morbidity and mortality of AOM, however, the emergence of antibiotic resistant middle ear microorganisms, has increased the suppurative sequelae.<sup>1-3</sup>

Acute coalescent mastoiditis (ACM) is a rare complication of acute otitis media. In severe AOM case, the mucosa in the epitympanum becomes hyperplastic and occludes the aditus ad antrum, entrapping purulent material within the mastoid air cells. As pus and granulation tissues accumulate, the pressure will crush the bony septation of mastoid air cells so they become necrotized and coalesce into a large coalescence of mastoid air cells, and becomes acute coalescent mastoiditis. The diagnosis of ACM is made based on clinical presentation and CT scan which showed destruction of the thin bony septae in mastoid air cells. When the infection penetrates through the mastoid cortex, a subperiosteal abscess could result. It may present as postauricular fluctuance or abscess.<sup>4,5</sup>

The objective of mastoidectomy for ACM is the evacuation of pus from the mastoid. The

removal of the cortical mastoid bone is carried out until the coalescence cortical mastoid cavity is encountered. The coalescent cavity is often only several millimeters under the surface of the mastoid cortex.<sup>6</sup>

The role of surgical treatment, and especially of mastoidectomy, in ACM is still questionable, as the recovery rate with intravenous antibiotics and myringotomy ranges between 60.4 and 87%. Some studies point out that no statistically significant differences are observed between the cure rates for children treated with myringotomy plus ventilation tube insertion and those managed more aggressively with mastoidectomies. On the contrary, an immediate drainage of the mastoid abscess could theoretically reduce the use of antibiotics and the hospital stay, and would prevent an intracranial complication. Other management options include the evacuation of the subperiosteal abscess by incision and drainage, exploratory puncture, or myringotomy. Mastoidectomy in AOM with subperiosteal abscess is also doubtful because of the high morbidity rate of such a procedure and the possible development of cholesteatoma and recurrent middle ear infections with hearing impairment, so the patients should be followed up closely post-surgery. Some experts recommend mastoidectomy only for severe complications or failures to improve with antibiotics and myringotomy. In our series the hospital stay and the duration of the antibiotic treatment were not significantly reduced when compared with more conservative approaches; this reflects the greater severity of the disease leading to a mastoidectomy. Reluctance to perform a mastoidectomy is

mainly related to the anesthesiological risks in small children, although excessive blood loss is very rare.<sup>7-9</sup>

The aim of this case report was to discuss the management of acute coalescence mastoiditis in a young patient with acute otitis media.

## CASE REPORT

A 10 months old boy was brought to the Ear Polyclinic, Department of Otolaryngology Head and Neck Surgery, Dr. Cipto Mangunkusumo Hospital, with chief complaint of bilateral profuse foul ear discharge, yellowish in colour. He had already come to ear polyclinic several times, and had been given oral antibiotics, but no improvement. In the last one week, there was a reddish swelling behind the left ear, which was tender when palpated, and his temperature was 41°C.

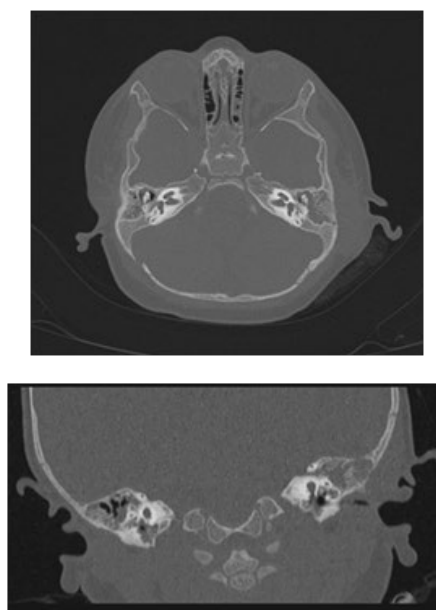
He was first brought to a district hospital and hospitalized for 5 days, and was given Cefotaxime 2 x 450 mg and Metronidazole 3 x 100 mg. On the second day there, the doctor did an incision and drainage on the retroauricular swelling, with negative culture result. On the 4<sup>th</sup> day, the antibiotic was changed to Ceftriaxone 2 x 500 mg. The laboratory test result taken on the 4<sup>th</sup> day were Hb 12 g/dL, hematocrit level 36%, leukocytes 26.800 and thrombocytes 710.000. The wound was covered with Gentamycin ointment and gauze. The parents asked for the patient to be referred to Cipto Mangunkusumo Hospital for second opinion and further treatment.

In clinical examination at Ear Polyclinic Cipto Mangunkusumo Hospital, there was a small quantity of clear, odorless mucous discharge on the left external ear canal. The retroauricular swelling was minimal, no fluctuation and no fluid coming out from the incision line. His CT scan evaluation showed a trabecular destruction of the left mastoid

which supported the diagnosis as acute coalescence mastoiditis. (Figure 1)

He was then hospitalized in ENT ward for further antibiotic therapy and clinical surveillance. On 48 hours observation, his general condition was *compos mentis*, normal heart and respiration rates, and temperature 36.5°C. The laboratory examination result showed Hb 11.5 g/dL, hematocrit level 34.2 %, leukocytes 8.160 and thrombocytes 191.000. Blood culture result was negative, and urine culture revealed *Enterococcus* sp. It was decided that mastoidectomy was not in order because the patient's condition was improving, and intravenous antibiotic treatment should be continued.

The patient was discharged after 14 days hospitalization. On the last examination there was no discharge from the external ear canals, and otoscopic examination revealed intact tympanic membrane on both ears. In the retroauricular region, the incision line was dry, no mark of inflammation and there was no sign of intratemporal complication such as facial paresis.



**Figure 1. Mastoid CT Scan**

## CLINICAL QUESTION

In acute coalescent mastoiditis affecting very young child as a complication of otitis media, could the disease be managed conservatively with intravenous antibiotic therapy without mastoidectomy operation?

## REVIEW METHODS

Evidence-based literature search with keywords “mastoidectomy”, “antibiotic” AND “coalescent mastoiditis” was performed through Pubmed, Proquest and Cochrane. The selection of literatures was based on inclusion and exclusion criteria. The inclusion criteria were 1) acute coalescent mastoiditis (ACM) in children as a complication of acute otitis media (AOM), and 2) diagnosis with CT scan of mastoid. The exclusion criteria were ACM in adult, ACM caused by non-acute otitis media such as chronic otitis media or congenital cholesteatoma.

## RESULT

The literature search obtained 37 articles in Pubmed, 240 articles in Proquest, none in Cochrane, which were relevant with the topic. Out of 37 articles screened with inclusion and exclusion criteria, 2 journals were in accordance with the reported case.

A research was conducted by Spremo et al.<sup>10</sup> in Bosnia (2007) on 13 patients with acute mastoiditis, aged between 1-15 years old. Diagnosis based on CT scan examination revealed coalescent mastoiditis on 10 cases. Mastoidectomy was performed on 6 coalescent mastoiditis cases.

Another research was carried out by Oestreicher-Kedem et al.<sup>11</sup> in Tel Aviv, Israel (2005) on 98 children with acute mastoiditis aged between 4 months - 14 years old. CT scan examination was performed on all cases with complication, and followed by mastoidectomy operation. All patients were

given intravenous antibiotic and myringotomy was performed on AOM cases. Changes in the antibiotic regimen were made in 28 cases because of nonresponse to treatment, or development of complication, or according to the culture results.

## DISCUSSION

The literature search obtained two articles relevant with our case. The research by Spremo et al.<sup>10</sup> reported 11 cases of coalescent mastoiditis diagnosed with CT scan examination. The highest number was between 6 - 10 years of age. Mastoidectomy was performed on 6 cases. There was no detail on antibiotic category chosen and the duration of administration, before the decision to do mastoidectomy. In cases of ACM which were underwent mastoidectomy there were 2 cases with intracranial complication. All cases were completely recovered after being assessed 3 months post treatment. Although there was no description about the duration of antibiotic administrations, the researchers suggest that ACM cases should primarily be given intravenous antibiotic for 48 hours to evaluate the improvement of symptoms. The indication for mastoidectomy surgery is the occurrence of complication on ACM cases, or ineffective conservative therapy.

The second research involved 98 children with acute mastoiditis. All cases were given intravenous antibiotic therapy and performed myringotomy. Antibiotic regimen of choice was cefuroxime, amoxicilline-clavulanat, ceftriaxone, vancomycine, ceftazidime, and ampicillin. Unlike the first research, CT scan was not performed in all ACM cases, but only in cases which developed complication, or nonresponsive to conservative treatment. Out of 98 cases, 16 patients developed complication such as subperiosteal abscess or intracranial complication. In subperiosteal abscess cases, mastoidectomy surgery was conducted. In cases with epidural or subdural abscess, and

sigmoid sinus thrombosis, mastoidectomy was also followed by neurosurgery to clean the intracranial process. All cases in this research were recovered. There was no report on the morbidity and hearing function post treatment.<sup>11</sup>

In our case, the external ear discharge and retroauricular abscess was the sign of progression of the disease. The retroauricular swelling was caused by blockage of aditus ad antrum, and it worsened the infection. Accumulation of purulent discharge in mastoid cavity caused bone necrosis, and it progress into the cortex of the mastoid and emerged as subperiosteal abscess. The diagnosis of subperiosteal abscess and other complications of ACM which should be made with temporal bone CT scan, had not been done in the district hospital. The literatures mentioned that CT scan examination should be performed in ACM cases with complication.<sup>10,11</sup>

After the abscess drainage procedure performed in the district hospital, the patient had showed clinical improvement. Tarantino et al.<sup>12</sup> stated that there was a common agreement about subperiosteal abscess should be drained to avoid further suppuration into the other vital organs. The combination of intravenous antibiotic administration, myringotomy, incision and drainage in acute mastoiditis with subperiosteal abscess, was reported to bring the recovery rate up to 92%.<sup>8</sup>

The management of our patient was administration of intravenous antibiotic, and the patient showed clinical improvement in symptoms, physical sign and laboratory result of decreased leukocyte counts. Mastoidectomy was not needed. Evidence based literature search suggested intravenous antibiotic administration without mastoidectomy operation could be conducted in ACM cases with 48 hours clinical condition surveillance.

In conclusion, coalescence mastoiditis cases without complication could be given intravenous antibiotic under 48 hours of

surveillance. Mastoidectomy surgery should be performed if there was a sign a clinical deterioration, such as intratemporal or intracranial complication.

## REFERENCE

1. Thorne MC, Chewaproug L, Elden LM. Suppurative complications of acute otitis media: changes in frequency over time. *Arch Otolaryngol Head Neck Surg.* 2009; 135(7): 638-41.
2. Pang LHY, Barakate MS, Havas TE. Mastoiditis in a paediatric population: A review of 11 years experience in management. *Int J Pediatr Otorhinolaryngol.* 2009; 73(11): 1520-4.
3. Zapalac JS, Billings KR, Schwade ND, Roland PS. Suppurative complications of acute otitis media in the era of antibiotic resistance. *Arch Otolaryngol Head Neck Surg.* 2002; 128(6): 660-3.
4. Mansour S, Magnan J, Nicolas K, Haidar H. Acute Otitis Media and Acute Coalescent Mastoiditis. In: *Middle Ear Diseases.* Springer International Publishing; 2018. p. 85-113.
5. Adhami M, Tohme S. Complications of acute otitis media in children: Case reports and review of literature. *J Med Liban.* 2010; 58(4): 231-7.
6. Haynes D, Wittkopf J. Canal wall up mastoidectomy. *Glascock-Shambaugh Surgery of the Ear.* Published online. 2010. p. 501-14.
7. Tamir S, Schwartz Y, Peleg U, Perez R, Sichel J-Y. Acute Mastoiditis in Children: Is Computed Tomography Always Necessary?. *Ann Otol Rhinol Laryngol.* 2009; 118(8): 565-9.
8. Tamir S, Shwartz Y, Peleg U, Shaul C, Perez R, Sichel J-Y. Shifting trends: mastoiditis from a surgical to a medical disease. *Am J Otolaryngol.* 2010; 31(6): 467-71.
9. Zanetti D, Nassif N. Indications for surgery in acute mastoiditis and their complications in children. *Int J Pediatr Otorhinolaryngol.* 2006; 70(7): 1175-82.
10. Spremo S, Udovčić B. Acute mastoiditis in children: susceptibility factors and

- management. *Bosnian J Basic Med Sci.* 2007; 7(2): 127-31.
11. Oestreicher-Kedem Y, Raveh E, Kornreich L, Popovtzer A, Buller N, Nageris B, et al. Complications of mastoiditis in children at the onset of a new millennium. *Ann Otol Rhinol Laryngol.* 2005; 114(2): 147-52.
  12. Tarantino V, D'Agostino R, Taborelli G, Melagrana A, Porcu A, Stura M. Acute mastoiditis: A 10 year retrospective study. *Int J Pediatr Otorhinolaryngol.* 2002; 66(2): 143-8.