

Case Report**Effectiveness of immediate primary correction and medial canthopexy in bilateral naso-orbito-ethmoid fracture****Al Hafiz, Dolly Irfandy, Bonny Murizky**Department of Otorhinolaryngology Head and Neck Surgery,
Faculty of Medicine Andalas University/M.Djamil General Hospital,
Padang**ABSTRACT**

Background: The naso-orbito-ethmoid (NOE) region is a functionally and aesthetically important area of the face. Traffic accidents are the most often cause of NOE fracture and contribute about 35 to 60% of cases. Clinical symptoms are associated with location and the impact. The best way to make an assessment is by clinical examination combined with 3D CT scan. The management usually required reconstruction of the injured anatomical structures of the face with Open Reduction and Internal Fixation (ORIF) method. **Purpose:** To report the result of immediate reconstruction surgery in a NOE fracture case. **Case Report:** A case of bilateral NOE fracture in a 24 years old woman, treated with ORIF. **Clinical Question:** Does immediate primary correction and medial canthopexy provides good result on face reconstruction of NOE fracture? **Review Method:** Literature searching through Cochrane database, Pubmed, Clinicalkey and Google Scholar, using keywords of correction procedure in NOE fracture, Open Reduction and Internal Fixation and medial canthopexy. **Result:** The search obtained 35 literatures published in the last 10 years, and found 21 articles relevant with the topics. **Conclusion:** NOE fracture is a fracture which often occurs as a result of traffic accidents. The diagnosis is established by anamnesis of patient's complaints and symptoms, physical examination, and 3D CT scan. Immediate reconstruction in NOE fracture cases gives a better result compared to delayed surgical management, as implemented in this case.

Keywords: Naso-orbito-ethmoid (NOE) fracture, Open Reduction and Internal Fixation (ORIF), immediate reconstruction

ABSTRAK

Latar belakang: Naso-orbito-ethmoid (NOE) adalah daerah yang penting pada wajah secara fungsional dan estetika. Kecelakaan lalu lintas merupakan penyebab terbanyak, dan menyumbang 35-60% angka kejadian dari fraktur NOE. Gejala klinis berhubungan dengan lokasi dan tingkat keparahan cedera. Cara terbaik mendiagnosis adalah dengan pemeriksaan klinis dan CT scan 3D. Penatalaksanaan dilakukan dengan rekonstruksi struktur anatomi wajah yang terluka, menggunakan metode reduksi terbuka dan fiksasi internal (Open Reduction and Internal Fixation/ORIF). **Tujuan:** Melaporkan keberhasilan rekonstruksi segera pada fraktur NOE. **Laporan kasus:** Dilaporkan satu kasus fraktur NOE bilateral pada seorang perempuan usia 24 tahun, yang dilakukan reduksi terbuka dan fiksasi internal. **Pertanyaan klinis:** Apakah rekonstruksi segera dan kantoepksi medial pada fraktur NOE memberikan hasil yang baik? **Metode telaah literatur:** Penelusuran berbasis bukti melalui database Cochrane, Pubmed, Clinicalkey dan Google Scholar menggunakan kata kunci rekonstruksi pada fraktur NOE, Open Reduction and Internal Fixation, dan kantoepksi medial. **Hasil:** Diperoleh 35 literatur yang terbit dalam 10 tahun terakhir, dan didapati 21 artikel yang relevan dengan topik. **Kesimpulan:** Fraktur NOE merupakan fraktur yang sering terjadi akibat kecelakaan lalu lintas. Diagnosis ditegakkan berdasarkan anamnesis mengenai keluhan dan gejala yang dirasakan pasien, pemeriksaan fisik serta pemeriksaan CT scan 3D. Penatalaksanaan pembedahan pada kasus fraktur NOE sesegera mungkin, memberikan hasil yang lebih baik dibandingkan dengan tindakan pembedahan tertunda, seperti yang tergambar pada kasus yang dilaporkan ini.

Kata kunci: fraktur *naso-orbito-etmoid (NOE)*, Open Reduction and Internal Fixation (*ORIF*), *rekonstruksi segera*

Correspondence Address: Al Hafiz, Department of Otorhinolaryngology Head and Neck Surgery, Faculty of Medicine Andalas University/Dr. M. Djamil General Hospital Padang. Email: alhafiz@med.unand.ac.id.

INTRODUCTION

Naso-orbito-ethmoid (NOE) region is an important area of the face for functional and aesthetical perspectives, and also to determine the width and projection of the face. NOE fracture represents the severity of injury, starting from a simple nasal bone fracture, minimally involving ethmoid, up to a comminuted fracture, and changes in the shape of facial structures, as a result of blunt force head trauma.^{1,2}

The most common cause of NOE fracture is motor vehicle accidents, contributing to deformity of the face about 35-60%. The complex anatomical form of paranasal sinus structures and the direction of the impact, often generate an antero-posterior fracture line causing injury in NOE complex which could affect ethmoid labyrinth, orbital wall, orbital soft tissue, and the skull base. This could cause an increase of intercanthal distance and produce post-trauma telecanthus.¹⁻³

The management of NOE fracture requires a total comprehension of human anatomy. Clinical examination should be performed meticulously with utmost precaution, including 3D CT scan and eye examination.^{2,3}

The accumulated information from all examinations, could be used as a guide in immediate open approach management, which provide precise reconstruction, and can produce a good result.^{1,3}

The purpose of this presentation is to report a case of NOE fractures which was successfully managed with immediate Open Reduction and Internal Fixation (ORIF).

CASE REPORT

Reporting a 24 years old female, who came to the Emergency Installation of Dr. M. Djamil General Hospital, Padang on August 29, 2017 with open nasal bone fracture caused by a hit from a concrete object 10 hours previously. Patient was conscious after the accident, with pain in the nose, open wound at the base of the nose, no complaint of hazy vision, no limited eye ball movement, and there was blood discharge from the nose and from the wound. Physical examination showed patient's condition was compos mentis, cooperative, Glasgow Coma Scale (GCS):15, heart rate 80x/minute, respiratory rate 18x/minute, body temperature 36.8° C, Visual Analog Scale (VAS): 5.

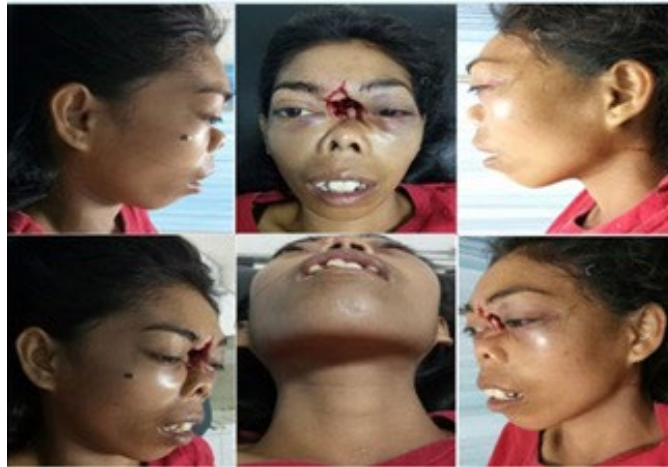Local ENT examination showed a bloody open nasal dorsum wound, fracture of nasal area with exposed bone, positive crepitation. The intercanthal distance was 34 mm. Septal fracture was present, no septal hematoma. Blood clot was present, but no active bleeding.

CT scan showed fractures of nasal and ethmoid bones, the medial wall of left orbita, and bilateral maxillary bones. Blood test showed normal range. The patient was diagnosed as bilateral NOE fracture and palpebral hematoma. Patient was given Tramadol in Ringer Lactate intra venous fluid drips (IVFD), Ceftriaxone, Anti Tetanus Serum (ATS), and Dexamethasone injections.

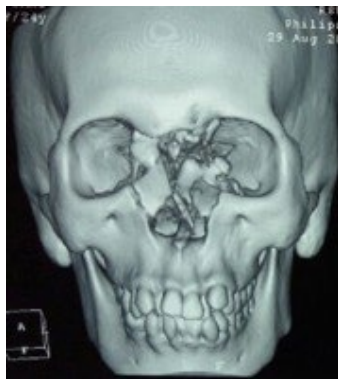
Ophthalmologic examination: visus ODS 20/20, bilateral palpebral edema and hematoma, bilateral conjunctival bleeding, normal bilateral intraocular tension, free bilateral ocular movement to all directions. Anel test did not show any fluid coming out

of the wound. The diagnosis was bilateral inferior and medial orbital walls and NOE

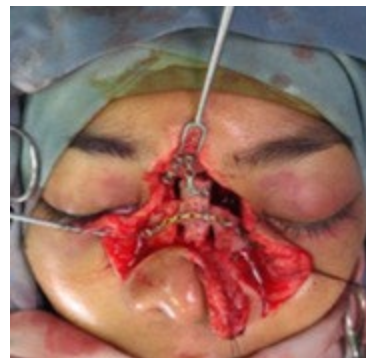fractures. She was given Cendo Lyteers and Chloramphenicol eye drops.



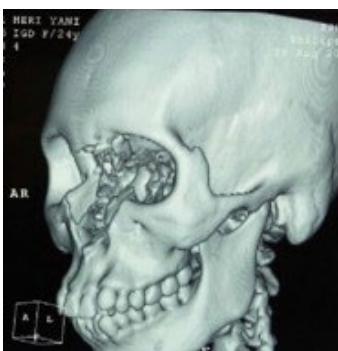Picture 1. Patient's face after the accident



Picture 2a. 3D CT scan AP position



Picture 3. Durante surgery



Picture 2b. Left oblique position

On the very same day, reconstruction surgery with open reduction internal fixation (ORIF) was executed, using mesh and flap from frontal region.

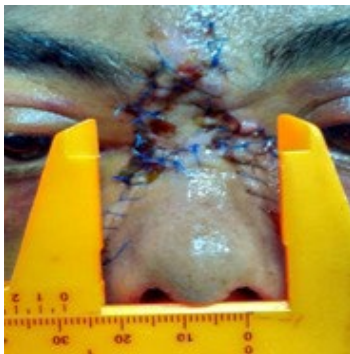Patient was under general anesthesia. The open wound was washed with NaCl 0.9%, and re-evaluated. Afterwards the nasal bone was drilled to install plate and screw, and also installing it at the side of nasal bone as a connector of right and left medial canthus.

Reconstruction of the nasal bone and orbital floor was fixated with 1.6 x 5 mm miniplate, and installing screws on the left and right maxilla bones, followed with stitching left medial canthus with PDS 4.0 thread, and fixated to the nasal bone (medial canthopexy). The wound was stitched using 4.0 chromic thread and closed with 5.0 prolene thread, followed by placing anterior nasal pack on both nasal cavities to fixate the nose and to control bleeding.

Postoperative diagnosis was: Post reconstruction surgery of left type 3 and of right type 2 NOE fractures, and bilateral orbital floor fractures and bilateral medial orbital wall fractures.

Postoperative ophthalmology examination: right and left eye visual acuity 20/20, slight bilateral palpebral edema and hematoma, left eye subconjunctival hemorrhage. Free bilateral eye movement to all directions.

On September 25, 2017, one month post operatively, the patient complained of blocked nose and decreased sense of smell, and upon examination it was found a swelling of the outer nose, and slight deformity. The medial alignment of the nose was good.



Picture 4. Intercanthal distance post reconstruction

On nasoendoscopic examination, the left nose cavity was spacious, eutrophic inferior concha and medial concha, and unblocked choanae. There was bloody mucoid post nasal drip and blood crust seen at the nasopharynx.

She was instructed to rinse the nose with NaCl 0.9%, 2 x 20 cc per day, and come for nose function evaluation once a month, up to 6 months. Should there be a problem, second stage surgery could be planned after 5 months.

CLINICAL QUESTION

“Does immediate primary correction and medial canthopexy provide good result on face reconstruction of NOE fracture?”

REVIEW METHOD

Literature search was performed through Cochrane database, Pubmed, Clinicalkey, and Google Scholar using keywords “Naso-orbito-ethmoid (NOE) fracture” AND “medial canthopexy” AND “immediate management in maxillofacial fracture”. The search was using inclusion criteria: 1) management of NOE fracture with ORIF reconstruction, 2) immediate management of maxillofacial fracture; and exclusion criteria: patients with other maxillofacial fracture besides NOE and orbital floor fractures.

RESULT

The search obtained 35 literatures which were published in the last 10 years, and found 21 articles relevant with the topics.

DISCUSSION

A study by Varun-Menon³ in India in 2014 found out that traffic accidents were the most frequent cause of NOE complex fracture, as many as 35-60% in facial bones, followed by other causes, such as violence actions, sport injury, and work accidents.

Elbarbary et al.⁴ concluded that transnasal approach for reposition of bone fragments which were connected with medial canthus tendon, to be an important step to restore the intercanthal distance.

Based on literature review, a delay in surgery of maxillofacial fracture management, in this case, NOE fracture, seldom provide good result. Should there be any delay for surgery, it must not more than two weeks.^{1,2}

One case of bilateral NOE fracture in a 24 years old female was reported. Injury in maxillofacial area happened quite often, and if such a case was not handled properly, it could affect psychosocial and functional wellbeing due to the fact that a face is vital for identity and esthetics of a person. Injury in this area

could impair bone structure and soft tissue in facial area. Udeabor⁵ in his study in 2014, obtained 135 maxillofacial fracture cases, and 46.5% caused by traffic accidents, followed by violence action (19.8%), and animal attack (1.2%).

Varun-Menon³ in India found that traffic accident was the most often cause of NOE complex fracture of facial bones (35-60%), followed by violence action, sport injury, and work accident.

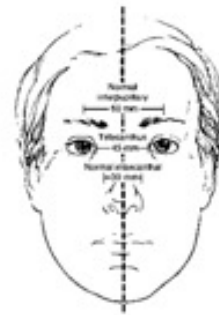Hard blow on the face, can cause a fracture in nasoethmoid area. NOE fracture can happen solitary or combined with other midfacial fractures, such as cribriform plate and fovea ethmoidalis fractures. In NOE fracture, the physician should be suspicious of the possibility of cerebrospinal fluid leak. Traumatic telecanthus might cause the rupture of medial canthal tendon. Inappropriate management of traumatic telecanthus will cause a permanent telecanthus, disappearance of nasal bridge and a descending palpebral position, and resulting in *enophthalmos* (posterior displacement of the eyeball within the orbit).⁶

In our case, the examination of the nose showed a bloody open nasal dorsum wound, fracture of nasal area with exposed bone, and positive crepitation. Nasal cavity examination showed septal fracture, no septal haematoma. Blood clot was present, but no active bleeding. Intercanthal distance was 34 mm. Normal intercanthal distance is 30-35 mm, and should the intercanthal distance >35 mm it is considered as telecanthus.² Therefore there was no posttraumatic telecanthus in this patient.

If medial canthal ligament had been severed from the bone, a transnasal canthopexy could be performed with microplate to stabilize the bone remnants and the tendon, using permanent stitching. Graft from patient's rib could be used for nasal bridge reconstruction. The access could be gained

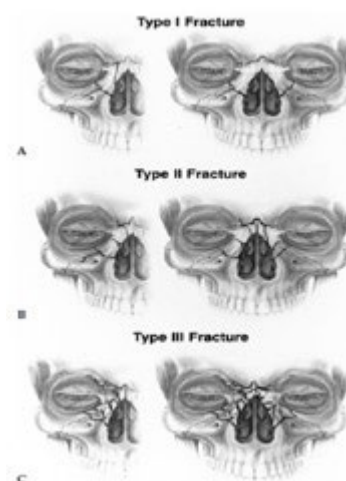
through an incision of medial canthus to open this area, or as an alternative, a coronal approach could be lengthened up to this area.⁶

In order to avoid posttraumatic telecanthus by fixating the medial canthus, the wound was stitched using PDS 4.0 thread from left medial canthus to nasal region.



Picture 5. Normal intercanthal distance is 30 to 35 mm.⁹

Good quality CT scan is a gold standard for NOE fracture management. It could evaluate the trauma case by assessing the hard blow causing sinus frontal and base of skull damages, and also to plan the fractures' reconstruction with 3 dimensional (3D) images.^{1,3} Three dimensional (3D) imaging combined with 2D CT scan increase the accuracy of NOE fracture detection.^{7,8} In our patient, during surgery the 3D CT scan was used to assess trauma, to navigate intraoperatively, and to confirm implant site.



Picture 7. Markowitz classification.⁹

Markowitz and Manson in 1991 made a classification scheme of NOE fracture based on the damage stage of center fragment and medial canthal tendon (MCT). In type I, the tendon is still attached to a relatively large bone fragment. In type II, the tendon attaches to more comminuted bone fragments that are difficult to manipulate at the reduction. Type III involves an avulsion of MCT from the bone where it is inserted. The most common NOE fracture is type I, whereas type II and III are less common. NOE type III is rare and accounts for only about 1-5% of all NOE fractures.⁹ This MCT avulsion has the most severe tendency and is associated with a very hard impacted injury.^{2,3,10,11} NOE Markowitz Type 1 and Type 2 fractures can be found unilaterally or bilaterally and characterized and indicated by medial canthal ligament which is still attached to the displaced bone fragment.^{4,12} This patient had type 3 fracture on the left side and type 2 NOE fracture on the right side of the face.

Management of closed nasal fracture could be carried out by closed reduction using Walsham forceps combined with digitally manipulation, followed by stabilization with inserted nasal packs and external gypsum. For open nasal fracture the management is by open reduction surgery with wire or miniplate fixation.^{4,13}

To reconstruct the shape and function of a defective nose, one has to select the proper procedure. Autograft is the gold standard for bone defects, but many factors should be considered for its implementation, as the survival of an autograft depends on many factors, such as donor site, the periosteum, rigid fixation, revascularization, location of transplantation and mechanical stress. Autograft is used for reconstructing severe defect, and it increases the length of time and surgery risk, such as morbidity and possibility of donor site complication.⁹

A study by Elbarbary⁴ concluded that the minimal time for follow up was six months.

CT scan examination should be repeated to assess the reconstruction result. The medial canthal distance ought to be measured and compared with the uninvolved side.

In postoperative follow up, it is important to check whether the fixation was stable, whether there is any disturbance of infraorbital nerve, lower eyelid ectropion, ptosis, epiphora, or infection occurred.

Damage of soft tissue in the eye lid can cause a disruption of the lacrimal gland system which often creates problems, such as epiphora or excessive tears. Epiphora was found on almost half of the cases, and besides due to lacrimal gland damage, could also be caused by bone fragment blockage, or soft tissue swelling. In mobile NOE fracture or avulsion of MCT, the lateral tension of the lower eyelid could be decreased into several levels.¹⁻³

Damage of lacrimal gland was found in 3-18% of nasoethmoid trauma patients, and they needed dacryo-cystorhinostomy along with the immediate reconstruction surgery.^{3,10}

If the correction surgery for maxillofacial trauma cases was postponed until the patient had been hospitalized, it was called a delayed correction and seldom gave good result.

The main reason to go for delayed measure was due to the difficulty of identifying the facial structures such as canthus ligament, nerve fibers, lacrimal drainage system, and the intricacy of mobilizing soft tissues. The advantage of delayed measure is enabling the edema to diminish. If the correction was performed while edema still exists, the incision line could be distorted.¹

In majority of cases, a 10 days delay in immediate measure could still provide good result. While in delayed reconstruction, callus formation has occurred causing deformity of the involved bones, which makes the surgery more difficult.¹⁻³

In our case, the face reconstruction surgery was executed several hours after patient's arrival at the hospital.

This patient underwent an open reduction surgery. Miniplates were installed to reunite the remaining bone fragments for reshaping patient's nose. No epiphora was found upon physical examination at admission, nor at postsurgery.

NOE fractures often happened as a result of traffic accidents. The diagnosis was established by anamnesis of patient's complaints and symptoms, physical examination, and 3D CT scan. Immediate correction surgery will provide better result compared to delayed measure.

REFERENCE

1. Ayliffe P, Booth PW. Nasoethmoid Fractures, in: Booth PW, Eppley BL, Schemelzeisen R. Maxillofacial Trauma and Esthetic Facial Reconstruction 2nd ed. Missouri: Elsevier Saunders; 2009. p. 209-21.
2. Hardt N, Kuttenger J. Classification of craniofacial fractures. In: Craniofacial Trauma, Diagnosis and Management. Berlin: Springer-Verlag; 2010. p. 38-54.
3. Varun-Menon P, Surej KKK, Kham SA. Naso-Orbito-Ethmoid Fractures: An overview. J Othoralynol-Head N. 2014 (2): 46-53.
4. Elbarbary A, Ali A. Functional and aesthetic restoration of medial canthal region following Naso-Orbito-Ethmoidal (NOE) traumatic telecanthus. J Plast Reconstr Surg. 2012; 36(2): 173-80.
5. Udeabor SE, Akinbami BO, Yarhere KS, Obiechina AE. Maxillofacial Fractures: Etiology, Pattern of Presentation, and Treatment in University of Port Harcourt Teaching Hospital, Port Harcourt, Nigeria. Hindawi Pub Corp Jour of Dental Surg. 2014: 1-5.
6. Thapliyal GK, Rajan HR. Management of Midfacial Fractures: An Overview. J postgraduate Med Educ Res. 2014; 48(2): 68-74.
7. Etemadi M, Shahnasari S, Soltani P, Motamedi MRK. Management of Naso-Orbital-Ethmoid fractures: A 10 year review. Med Sci, Iran. 2017; 22(3) e29230: 1-9.
8. Akadiri OA. Naso-Orbito-Ethmoid Fractures: Perspective and Practices of Nigerian Surgeons. Ann Ibd. Pg. Med. 2012;10(2): 40-7.
9. Strong EB, Sykes MJ. Frontal Sinus and Nasoorbitoethmoid Complex Fractures. Papel ID, Frodel J, Holt GR, Larrabee WF, Nachlas N, Park SS, et al. eds. Facial Plastic Reconstructive Surgery. 2nd ed., Maryland: Thieme Medical Pub.; 2002. p. 754-8.
10. Nguyen M, Koshy JC, Hollier LH. Pearls of Nasoorbito-ethmoid Trauma. Baylor Coll of Med, Houston, Texas. 2010: 383-8.
11. Wei J, Tang ZL, Liao XJ, Yu YB, Jing W. The Management of Naso-Orbital-Ethmoid (NOE) fractures. West China Hosp of Stomatology, Sichuan Univ. 2015. p. 296-301.
12. Shenoy A. Technical Note- A Novel Approach to Treat Markowitz Type 1 and Type 2 Naso-Orbito Ethmoidal Fractures Using Minimally Invasive Transcutaneous periosteal Plates. Glob J Otolaryngol ori art, India, 2017; 10(4): 1-3.
13. Baliga SD, Urolagin SD. Transnasal Fixation of NOE Fracture: Minimally Invasive Approach. J Maxillofac. Oral Surg Jour. 2012; 11(1): 34-7.